

THE JOURNAL OF BONE & JOINT SURGERY

# J B & J S

*This is an enhanced PDF from The Journal of Bone and Joint Surgery*

*The PDF of the article you requested follows this cover page.*

---

## **Current Concepts Review - Tendinosis of the Elbow (Tennis Elbow). Clinical Features and Findings of Histological, Immunohistochemical, and Electron Microscopy Studies**

BARRY S. KRAUSHAAR and ROBERT P. NIRSCHL  
*J Bone Joint Surg Am.* 1999;81:259-78.

---

**This information is current as of January 29, 2010**

### **Reprints and Permissions**

Click here to [order reprints or request permission](#) to use material from this article, or locate the article citation on [jbjs.org](http://jbjs.org) and click on the [Reprints and Permissions] link.

### **Publisher Information**

The Journal of Bone and Joint Surgery  
20 Pickering Street, Needham, MA 02492-3157  
[www.jbjs.org](http://www.jbjs.org)

## Current Concepts Review

# Tendinosis of the Elbow (Tennis Elbow)

CLINICAL FEATURES AND FINDINGS OF HISTOLOGICAL, IMMUNOHISTOCHEMICAL,  
AND ELECTRON MICROSCOPY STUDIES\*

BY BARRY S. KRAUSHAAR, M.D.†, EMERSON, NEW JERSEY, AND ROBERT P. NIRSCHL, M.D., M.S.‡, ARLINGTON, VIRGINIA

*Investigation performed at Nirschl Orthopedic Sportsmedicine Clinic, Arlington; Arlington Hospital, Arlington;  
and Georgetown University Medical Center, Washington, D.C.*

Tendon injuries can be divided into several categories on the basis of the nature of their onset and the tissues involved. Acute tendon injuries, such as laceration of the flexor tendons of the fingers, are traumatic in nature. Chronic overuse injuries are the result of multiple microtraumatic events that cause disruption of the internal structure of the tendon and degeneration of the cells and matrix, which fail to mature into normal tendon; at times, such injuries result in tendinosis<sup>35</sup>. The healing of acute tendon injuries has been studied from the perspective of the body's response to lacerations of flexor tendons as well as after operative intervention<sup>35,67</sup>.

Tendinosis is incompletely understood. Although the term tendinitis is used frequently and often indiscriminately, histopathological studies have shown that specimens of tendon obtained from areas of chronic overuse do not contain large numbers of macrophages, lymphocytes, or neutrophils<sup>26,35,59</sup>. Rather, tendinosis appears to be a degenerative process that is characterized by the presence of dense populations of fibroblasts, vascular hyperplasia, and disorganized collagen. This constellation of findings has been termed angiofibroblastic hyperplasia<sup>48</sup>. It is not clear why tendinosis is painful, given the absence of acute inflammatory cells, nor is it known why the collagen fails to mature. If it can be assumed that tendinosis has essentially the same pathogenesis regardless of where it occurs in the body, then the examination of specimens from patients who have tennis elbow can serve as a model for the investigation of pain in other regions in which tendinosis has been reported, such as the rotator cuff, the Achilles tendon, the patellar ligament, the adductors of the hip, the triceps, the flexors and extensors of the elbow, and the plantar fascia<sup>7,26,27,35,43,46,57,66</sup>.

\*No benefits in any form have been received or will be received from a commercial party related directly or indirectly to the subject of this article. No funds were received in support of this study.

†Orthopaedic and Sports Medicine Associates, 440 Old Hook Road, Emerson, New Jersey 07630.

‡Nirschl Orthopedic Sportsmedicine Clinic, 1715 North George Mason Drive, Arlington, Virginia 22205. E-mail address for Dr. Nirschl: nirschl@erols.com.

The term angiofibroblastic tendinosis refers to the degenerative changes that occur when a tendon has failed to heal properly after an injury or after repetitive microtrauma resulting from overuse. Tendinitis is characterized by the presence of an increased number of lymphocytes or neutrophils. Tendinosis is characterized by the presence of active fibroblasts and vascular hyperplasia.

Tendons involved in locomotion and ballistic performance, which transmit loads under elastic and eccentric conditions, are susceptible to injury. Some tendons, such as those that wrap around a convex surface or the apex of a concavity, those that cross two joints, those with areas of scant vascular supply, and those that are subjected to repetitive tension, are particularly vulnerable to overuse injuries<sup>10,35,45,66,70,72</sup>.

Tennis elbow, or lateral epicondylitis, is a well known example of an injury in such a region. Cyriax<sup>11</sup> noted that the origin of the extensor carpi radialis brevis was the primary site of this injury, and pathological changes have been consistently documented at this location<sup>9,20,48,59</sup>. One-third of patients also have involvement of the origin of the extensor digitorum communis<sup>11,48,59</sup>. While the terms epicondylitis and tendinitis commonly are used to describe tennis elbow, histopathological studies have demonstrated that tennis elbow is not an inflammatory condition; rather, it is a fibroblastic and vascular response called angiofibroblastic degeneration, now more commonly known as tendinosis<sup>46</sup>. The importance of distinguishing tendinosis from tendinitis is more than just a need for semantic accuracy. Proper treatment depends on a correct understanding of the nature of the injury and the goals of therapeutic intervention. In the present report, we will discuss our histopathological findings related to tendinosis of the elbow and identify points of similarity and dissimilarity between these findings and those of previous studies.

### Pathophysiology of the Healing Response

The overall concept of the healing response in the human body is that, after disruption of normally ho-

meostatic structures, the cells of the body are activated to mobilize materials that are used to reconstruct damaged tissues<sup>16,35</sup>. The healing response has been well documented<sup>35,56,71</sup> in the context of tendon lacerations. Laceration of a tendon is followed by structural disruption, bleeding, and a healing cascade that occurs over a period of months. Structures surrounding the tendon provide a fibroblastic and vascular component for healing, with contributions from macrophages and endotenon-based fibroblasts. An extrinsic response is quickly enlisted from the blood-borne cellular and chemical systems related to the clotting cascade as well as from the macrophage-based inflammatory and immune-response systems<sup>16,35,45,66</sup>.

The word inflammation is misleading when tendon-healing is discussed. Although Celsus (A.D. 14-37) described inflammation as "rubor et tumor cum calor et dolor," the healing of a lacerated tendon is not comparable with chronic inflammatory conditions, such as rheumatoid arthritis, which are characterized by lymphocyte and neutrophil reactions<sup>11,16,18,35</sup>. Rather, as Mason and Allen<sup>38</sup> noted in 1941, tendon-healing is exudative and formative, and, as Ross<sup>60</sup> observed in 1968, the phases of healing can be described as inflammation, proliferation, and organization. Interestingly, remodeling may be considered a continuous process during tendon-healing because tension across fibroblasts causes these cells to divide and to align perpendicular to the line of stretch. This concept extends into an analogy of Wolff's law, which states that tension on maturing granulation tissue may lead to the development of a preferential direction of collagen in the fibers<sup>4,13,14,18,35,45,70</sup>.

Debate has centered on whether lacerated tendons heal by means of an entirely extrinsic cellular response or whether an intrinsic healing response is involved as well<sup>35,54,56,67</sup>. Recent studies have shown that an extrinsic inflammatory response is not essential for tendon-healing and that tendons have an intrinsic capacity to heal<sup>18,34,36</sup>. It has been postulated that lacerated tendons heal through a combination of extrinsic and intrinsic pathways<sup>35,71</sup>. Because all of the layers of the tendon are violated and blood is known to enter the region of injury, it is possible that humoral chemical mediators join the local healing response<sup>35</sup>.

The previous description of tendon-healing is based on an acute injury such as a laceration or a full-thickness tear, lesions that are not commonly encountered in non-contact sports. In contrast, the common repetitive overuse injury is a chronic microtraumatic event; tennis elbow is an example of such an injury<sup>48</sup>. When tennis elbow is associated with a sudden onset of pain, it is likely that there has been an acute worsening of an accumulated series of microscopic injuries within the tendon. This concept is supported by evidence that approximately two-thirds of acute ruptures of the Achilles tendon are associated with histological evidence of

chronic pathological changes within the tendon<sup>26,27</sup>. Repetitive overuse of a tendon can be viewed as a situation in which the normal tolerance of the tendon to stress is exceeded<sup>12,35</sup>. It is believed that if the mechanism of repair is controlled, tendon fibroblasts make increased collagen and cross-linkages in response to internal microtears.

Eccentric movements are thought to be the primary (although not necessarily the only) cause of internal microtears<sup>8</sup>. The viscoelastic properties of tendon are dependent on the rate of contraction<sup>45</sup>. When the tolerable rate of stretch of the tendon fibers is exceeded, the internal stress becomes greater than the ultimate tensile strength of the tendon, resulting in a tear. A net increase of more than 8 percent of the total length of the tendon also results in a tear<sup>26</sup>. Tendon-tearing may involve side-to-side dehiscence of the fascicles or actual longitudinal disruption of the fibers.

### Pathogenesis of Tendinosis

In the case of tennis elbow, the cellular response to internal microtears leads to tendinosis. One of us (R. P. N.) previously categorized the stages of repetitive microtrauma<sup>43</sup>. A stage-1 injury is probably inflammatory, is not associated with pathological alterations, and is likely to resolve; a stage-2 injury is associated with pathological alterations such as tendinosis, or angiofibroblastic degeneration; a stage-3 injury is associated with pathological changes (tendinosis) and complete structural failure (rupture); and a stage-4 injury exhibits the features of a stage-2 or 3 injury and is associated with other changes such as fibrosis, soft matrix calcification, and hard osseous calcification. The changes that are associated with a stage-4 injury also may be related to the use of cortisone.

In practice, it is the second stage (angiofibroblastic degeneration) that is most commonly associated with sports-related tendon injuries such as tennis elbow and with overuse injuries in general. Within the tendon, there is a fibroblastic and vascular response (tendinosis) rather than an immune blood-cell response (inflammation). Thus, the terms epicondylitis and tendinitis are misnomers<sup>48</sup>. Although it is commonly presumed that any painful structure is inflamed, connective-tissue pain can be perceived by the patient as the result of nociception and a noxious chemical environment<sup>35</sup>.

One of us (R. P. N.) postulated that some patients who have tennis elbow may have a genetic predisposition that makes them more susceptible to tendinosis at multiple sites<sup>41</sup>. He termed this condition mesenchymal syndrome on the basis of the stem-cell line of fibroblasts and the presence of a potentially systemic abnormality of cross-linkage in the collagen produced by the fibroblasts. Patients may have mesenchymal syndrome if they have two or more of the following conditions: bilateral lateral tennis elbow, medial tennis elbow, cubital tunnel syndrome, carpal tunnel syndrome, de

Quervain tenosynovitis, trigger finger, or rotator-cuff tendinosis<sup>41,45</sup>.

#### **Pathological Changes Associated with Tendinosis**

The histopathological features of tendinosis as described by Goldie<sup>20</sup> were further characterized by one of us (R. P. N.) and Pettrone<sup>42</sup> as angiofibroblastic tendinosis, which is a distinctly noninflammatory, degenerative, avascular process associated with the formation of disorganized and immature collagen as well as immature fibroblastic and vascular elements. Some authors have described tendinosis as a degenerative process and others have described it as a dysfunctional, immature tendon repair<sup>24-27,35,42,55,66</sup>. Regardless of what it is called, tendinosis is the result of failed tendon-healing.

Normal tendon contains bundles of type-I collagen that are oriented along the long axis of the tendon in a tightly packed, highly ordered fiber matrix that is ideal for transmitting load<sup>72</sup> (Fig. 1). Between the rows of collagen, there is a sparse number of spindle-shaped, long, thin tendon fibroblast cells with dark cytoplasm; these cells are arranged longitudinally, parallel to the long axis of the tendon<sup>21,66,72</sup>. Normally, tendon fibers are composed of collagen fibrils embedded in a matrix of proteoglycans, glycosaminoglycans, and water with few cells. A loose connective tissue containing visceral and parietal layers surrounds the entire tendon. Vascularized tendons are surrounded by epitenon with capillaries. Small penetrating vessels perforate the endotenon and stop at the parietal paratenon<sup>18,26,45</sup>.

Tendinosis is characterized by hypertrophy of fibroblasts, abundant disorganized collagen, and vascular hyperplasia in what are, under normal circumstances, avascular tendon fascicles (Fig. 2). Goldie<sup>20</sup> described an invasion of round cells, fibroblasts, and vessel tufts as being pathognomonic of epicondylitis. Sarkar and Uhthoff<sup>83</sup> observed mesenchymal cells and a plethora of tenoblasts, and Regan et al.<sup>59</sup> described tendinosis as an immature reparative process set in a background of focal hyaline degeneration. One of us (R. P. N.) and Pettrone<sup>42,46,48</sup> described tendinosis as the disruption of normally orderly tendon fibers by a characteristic pattern of invasion by fibroblasts and atypical granulation tissue. Those authors termed the condition angiofibroblastic tendinosis because angiofibroblastic tissue was found to be insinuating itself through abnormal hypercellular regions and extending focally into adjacent normal-appearing tendon fibers. Acute inflammatory cells almost always were absent, but chronic inflammatory cells occasionally were scattered in the surrounding fibrous connective tissue and even in the muscular tissue (a finding that was consistent with myositis). Other authors have agreed that operative specimens obtained from patients who have tendinosis do not show characteristic signs of inflammation; rather, the tissue lacks macrophages and neutrophils and is characterized by an

abnormal matrix, increased vascularity, and fatty, mucoid, or hyaline degeneration<sup>8,26,27,35,57</sup>.

#### *Cellularity in Tendinosis*

The predominant type of cell in tendinosis is a mesenchyme-derived tendon fibroblast (tenocyte)<sup>59,62,63,67</sup>. These fibroblasts are plump and have a decreased nucleus-to-cytoplasm ratio compared with normal tenocytes. The cytoplasm has been found to exhibit blast-like changes (vacuolation), suggesting dedifferentiation from resting fibroblasts as well as cellular activity<sup>27,35</sup>. Regan et al.<sup>59</sup> reported mitochondrial calcification and loss of definition of the rough endoplasmic reticulum, as might be seen in cells that are actively manufacturing protein or collagen. The presence of abundant Golgi vesicles is consistent with the extracellular transmission of cellular products.

In the present study, light microscopy of sections that had been stained with hematoxylin and eosin demonstrated fibroblastic hyperplasia (Fig. 3). Sections that had been stained for elastin with modified Verhoeff-van Gieson stain revealed nests of well defined fibroblasts, whereas those that had been stained with Masson trichrome and vimentin stain showed permeative fibroblastic hyperplasia throughout regions that had appeared nearly normal on the sections that had been stained with hematoxylin and eosin (Figs. 4, 5, and 6). Dedifferentiation of tenocytes was best seen on the specimens that had been stained with toluidine blue<sup>27</sup>. The cells were plump, with pale and increased cytoplasm (Fig. 7).

Electron microscopy of the fibroblasts revealed many vacuoles, open nuclear chromatin, abundant production of collagen along the periphery of the cells, and, interestingly, contractile elements within some of the fibroblasts as are seen with myofibroblasts, cells that are not native to tendon. Thus, we could identify two populations of fibroblasts: those with intracellular contractile elements and those without them, with the latter type having a more normal appearance (Figs. 8 and 9). Both types of fibroblasts had lysosomes and fatty vacuolation, with abundant endoplasmic reticulum<sup>26,63</sup>.

Neither light microscopy nor electron microscopy revealed any spatial orientation of fibroblasts in relation to the direction of collagen fibers, although many fibroblasts were found near cleavage planes in the tendons as well as in perivascular areas. Sarkar and Uhthoff<sup>83</sup> identified myofibroblasts near vascular regions, and we saw these cells close to and at a distance from blood vessels.

#### *Vascularity in Tendinosis*

The normal vascular supply of tendons is derived from capillaries and nerves that penetrate the epitenon and endotenon but not the parietal paratenon that surrounds individual tendon fascicles<sup>18,42</sup>. The extensor carpi radialis brevis is a vascular tendon; thus, it does not

derive its nutrition from a synovial sheath. Normally, nerves and vessels do not penetrate the individual fascicles of the tendon.

The vascular hyperplasia that is associated with tendinosis was noted by Goldie<sup>20</sup> and was later described by one of us (R. P. N.)<sup>45</sup> as exhibiting a characteristic pattern of invasion by atypical granulation tissue in which the vessels are abnormal or immature. A number of authors have described a proliferative arteriolitis with some deposition of fibrin and the formation of a thrombus, with obliteration of the lumen of the vessel<sup>24-27</sup>. Leadbetter<sup>35</sup> reported ingrowth of vessels accompanied by mesenchymal cells (pericytes) as well as epithelial hyperplasia with formation of microscopic thrombi. Regan et al.<sup>39</sup> concluded that the vascular hyperplasia was evidence of an immature repair process.

In the present study, light microscopy of sections that had been stained with hematoxylin and eosin consistently revealed vascular hyperplasia within regions of tendinosis (Figs. 2 and 3). Vessel-like structures were observed parallel to clefts that had formed between tendon fascicles; these structures were lined with mesenchymal cells but did not have a continuous lumen. In other areas, small-lumen vessels were surrounded by swirls of abnormal collagen and dense populations of fibroblasts. Light microscopy of sections that had been stained with Masson trichrome and vimentin stain revealed that the vascular hyperplasia was much more widespread and disorganized than it appeared on sections that had been stained with hematoxylin and eosin (Figs. 5 and 6). There was no apparent direction to the vascularity, nor was there any evidence of a connection between the vessel-like structures.

Immunohistochemical studies that were performed with smooth muscle antigen (SMA) enhanced the more mature vascular elements regardless of whether the vessels in the area of tendinosis were the result of extrinsic capillary ingrowth or the product of an intrinsic mesenchymal reaction. Thus, vascular hyperplasia in regions of tendinosis is not an entirely immature response (Fig. 10). It is not known if the vessels observed in areas of tendinosis are capable of sustaining blood flow or if such blood flow would be sufficient to sustain the remodeling process of tendon-healing. Only the walls of the larger vessels stained positively for elastin. We suspect that elastin develops in the walls of more mature vessels and that the immature vessels seen in regions of tendinosis represent a structurally incomplete process (Fig. 4). Thus, the tissue found in regions of tendinosis is not avascular; however, the vascular structures do not function like blood vessels.

In the present study, the vascularity of tendinosis was abnormal when visualized with the electron microscope. Blood vessels had reduplicated and thickened basal lamina. At times, the lining cells (pericytes) appeared several layers thick and contained contractile elements as well as lipid vacuoles and rich endoplasmic

reticulum<sup>27</sup>. Some vessels had smooth and regular inner walls, whereas others had gaps in the basal lamina and between the pericytes. The channels contained occasional erythrocytes but had no true basal lamina. Many vessels had a constricted or obliterated lumen<sup>27,62,67</sup>. Few perivascular plasma cells, macrophages, or lymphocytes were found, and no neutrophils were detected (Figs. 11 and 12). The collagen matrix in the regions surrounding the vascular hyperplasia was of poor quality, and the vessels commonly were seen in the most abnormal-appearing areas of collagen. Thus, the vascular hyperplasia in tendinosis is not associated with improved healing.

#### *Collagen in Tendinosis*

It is reasonable to consider the vascular and fibroblastic hyperplasia in tendinosis as a physiological response to disruption of the collagen structure. The structure and physiology of normal tendon collagen has been well described in several recent studies<sup>17-19,26,69,72</sup>. The ribosomes in the fibroblast assemble amino acids (predominantly glycine, proline, and hydroxyproline) into a primary structure of tropocollagen. This linear structure takes on the secondary quality of a left-handed configuration. The tertiary structure is made of tropocollagens that are coiled to form a right-handed helix. This product, secreted by Golgi vesicles and trimmed enzymatically of its carboxyl and amino terminals extracellularly, lines up alongside other procollagen molecules in a quarter-stagger arrangement (creating a quarternary structure), as determined by regular association with adjacent molecular acidic and basic amino acids.

Five collagen molecules make up a single microfibril of tendon<sup>19,35,40,66,72</sup>. Normally, microfibrils form subfibrils, fibrils, and fascicles, in increasing order of size. These collagen subunits are internally bound by a matrix of proteoglycans and glycosaminoglycans. They are maintained by a sparse population of tendon fibroblasts that surround individual fibrils within each fascicle, and these fibroblasts are nourished by the longitudinal system of capillaries at the paratenon level<sup>26,70</sup>. The ultimate structure of tendon is a three-dimensional one. When a tear occurs within a tendon fascicle, it disrupts a normally balanced system in a manner somewhat analogous to a stress fracture in bone. Similar to a stress fracture, which heals either by the physiology of local osteons or through a formal system of callus formation, the cells of a tendon fibril are stimulated to heal either internally or by forming a temporary layer of granulation tissue that later remodels to become tendon.

The collagen in tendinosis is abnormal both grossly and on examination with light and electron microscopy. The treatment (resection and repair) of tendinosis of the elbow depends on the visual identification of tissue that is dull, gray, and soft compared with shiny, white, firm, normal-appearing tendon<sup>42</sup>.

Abnormalities of collagen in tendinosis have been




FIG. 1

Photomicrograph of a specimen of normal tendon, showing parallel bundles of uniform-appearing collagen oriented along the long axis of the tendon. The matrix, which is composed primarily of proteoglycans, glycosaminoglycans, and water, is stained evenly. No vascular structures are apparent within the tendon (hematoxylin and eosin,  $\times 100$ ).

noted by several authors. Sarkar and Uthoff<sup>62,63</sup> described the matrix as being in a reactive state and having signs of ongoing repair of a degenerative process.

Regan et al.<sup>59</sup> saw evidence of an immature reparative process set in a background of focal hyaline degeneration. Leadbetter<sup>35</sup> reported disorganization of the

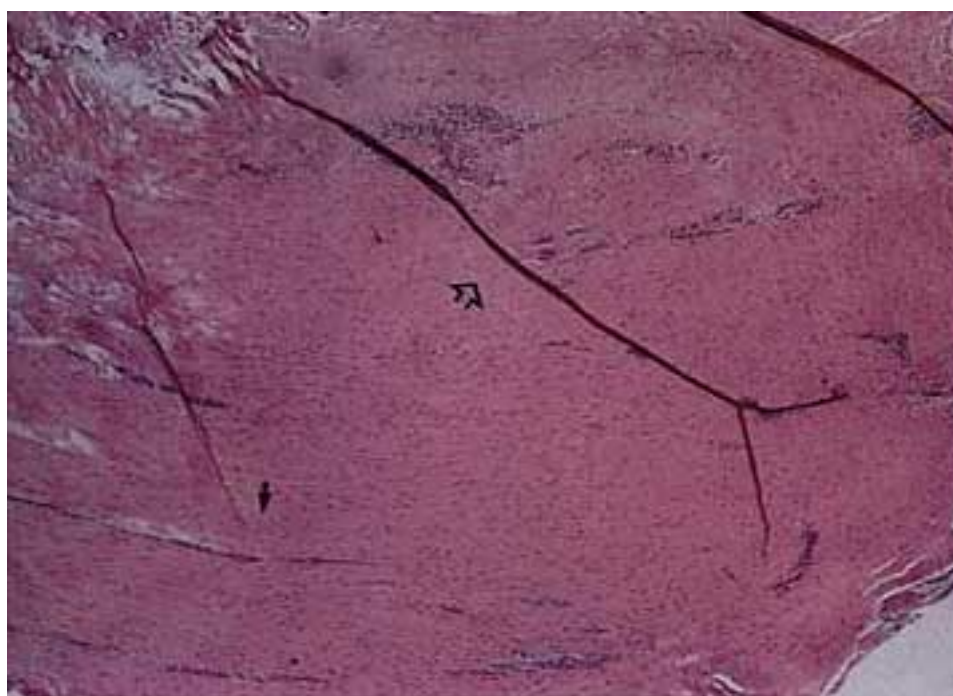


FIG. 2

Photomicrograph demonstrating tendinosis of the extensor carpi radialis brevis tendon. The entire specimen appears to be hypercellular, with focal areas that are densely cellular. Some of the hypercellular regions are parallel to the tendon fibers (solid arrow), whereas others are not (open arrow). There is no evidence of an inflammatory response, as indicated by the absence of polymorphonuclear leukocytes, lymphocytes, and macrophages (hematoxylin and eosin,  $\times 20$ ).

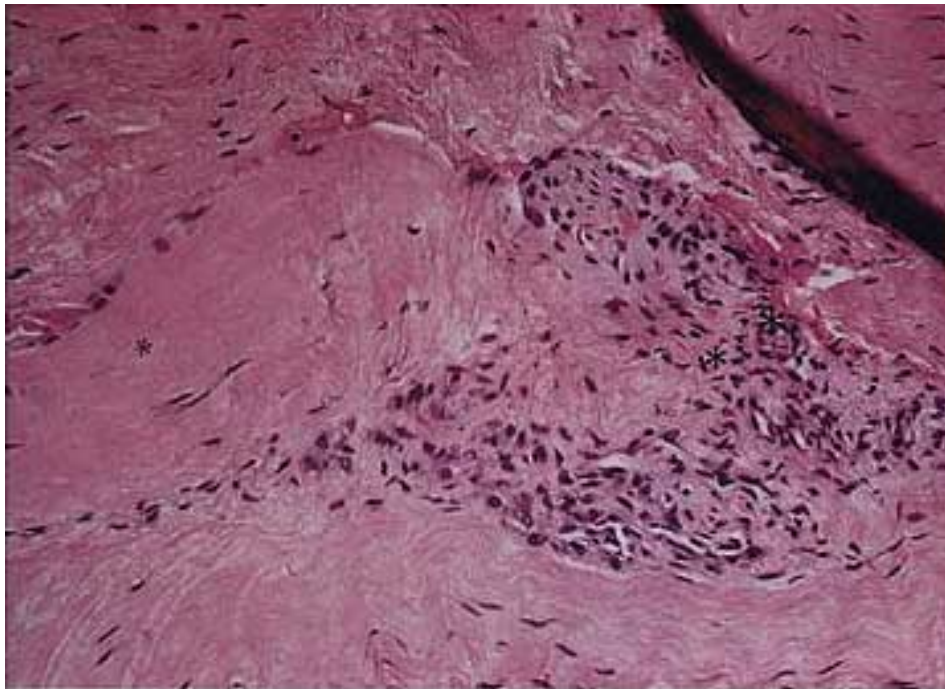


FIG. 3

Photomicrograph showing an enlarged view of the area around the open arrow in Fig. 2. The area in which angiofibroblastic hyperplasia (right asterisk) meets normal tendon (left asterisk) contains active fibroblasts that are randomly oriented and appear to be infiltrating the surrounding tissue. Disorganized collagen (middle asterisk) abuts normal-appearing collagen. The matrix within the pathological areas is loose and pale in appearance (hematoxylin and eosin,  $\times 100$ ).

collagen fibers with microtears and signs of repair and hyaline degeneration. One of us (R. P. N.) and Pettrone<sup>42</sup> also noted the formation of disorganized and immature

collagen and suspected a mesenchymal cell-derived failure of collagen cross-linkage. Teitz et al.<sup>66</sup> reported that the matrix in areas of tendinosis was disorganized and

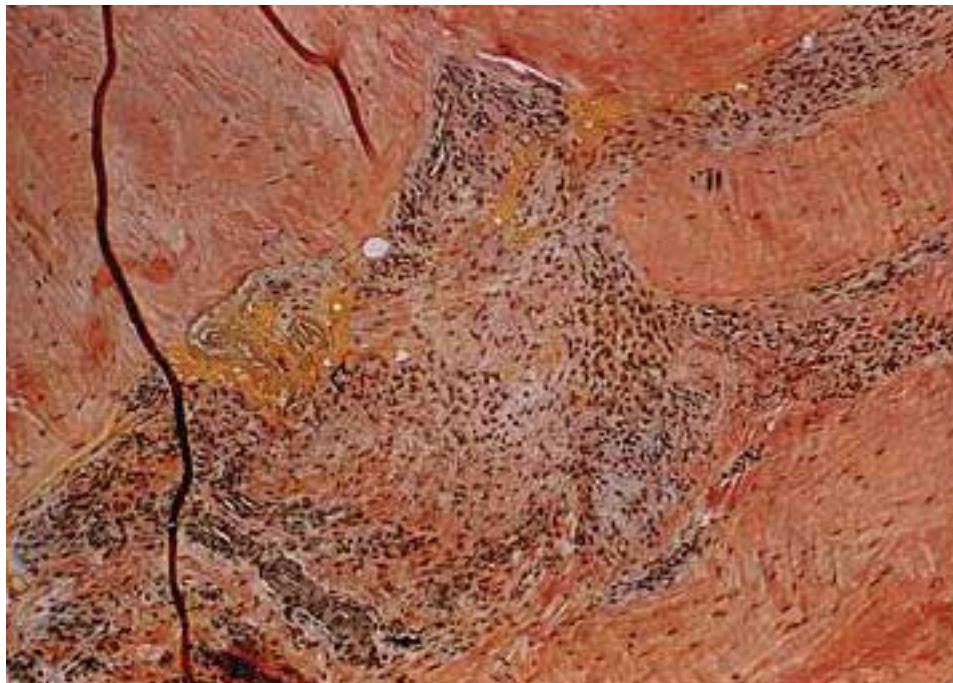


FIG. 4

Photomicrograph showing that the maturing vessel walls (single solid arrow) in areas of tendinosis stain darkly for elastin. The areas of fat (open arrow) within tendon fascicles are an abnormal finding. The infiltrative appearance (double solid arrow) of tendinosis and the distinct boundary of normal tendon suggest a reparative and regenerative process ( $\times 40$ ).

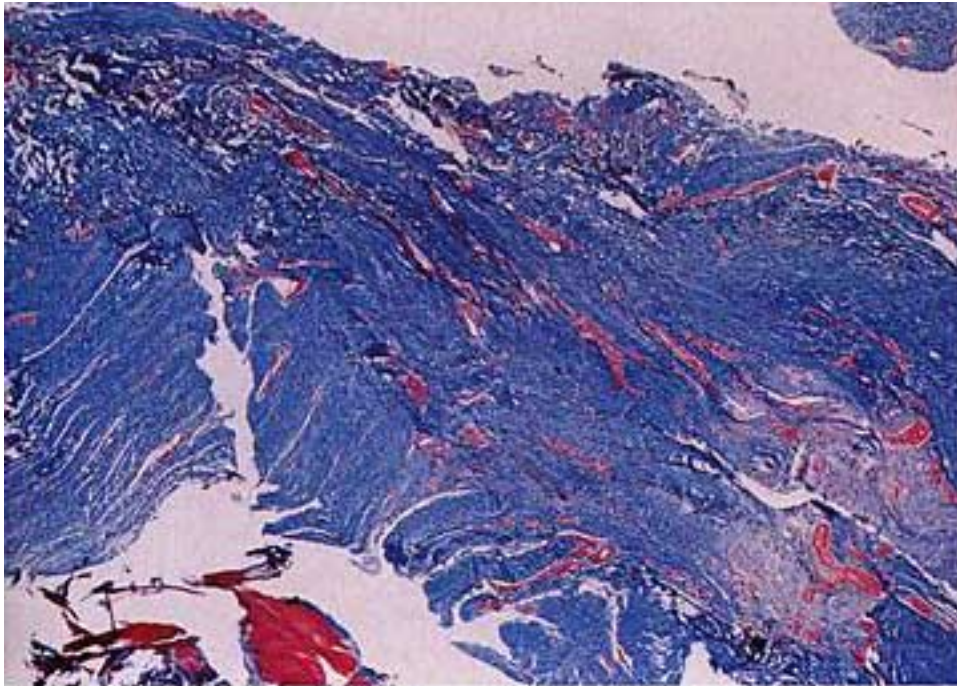


FIG. 5

Photomicrograph of a specimen from a patient who had severe tendinosis. The pale-blue regions indicate abnormal collagen and matrix production. Densely cellular regions (indicated by the red stain) reveal angiofibroblastic hyperplasia permeating the tendon in linear clefts and clusters. The appearance of this specimen should be contrasted with that of the specimen in Fig. 4, which shows a focal area of tendinosis in a more normal-appearing background (Masson trichrome,  $\times 10$ ).

lacked the usual axial, tightly woven bundles. In the present study, we noted similar findings but also found that multiple levels of magnification and staining techniques revealed not only structural disruption and an

incomplete repair process but also a physiological loss of communication between the local healing process and the normal tendency of the body to restore the original structure.

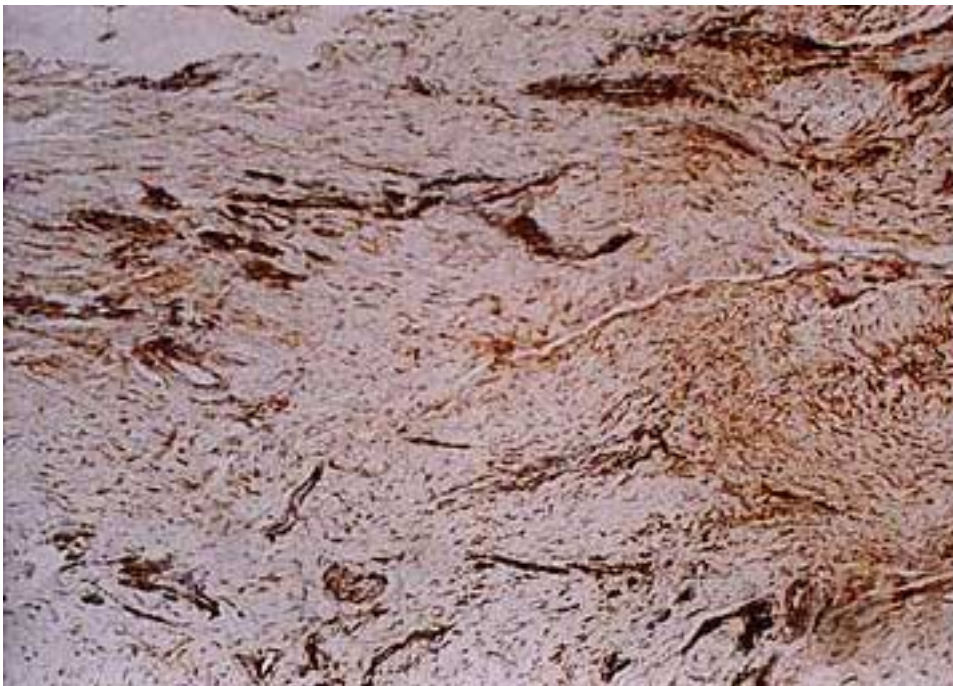


FIG. 6

Photomicrograph demonstrating the permeative nature of tendinosis. This finding is indicated by the presence of widespread cellularity and randomly oriented vascular hyperplasia (vimentin,  $\times 40$ ).



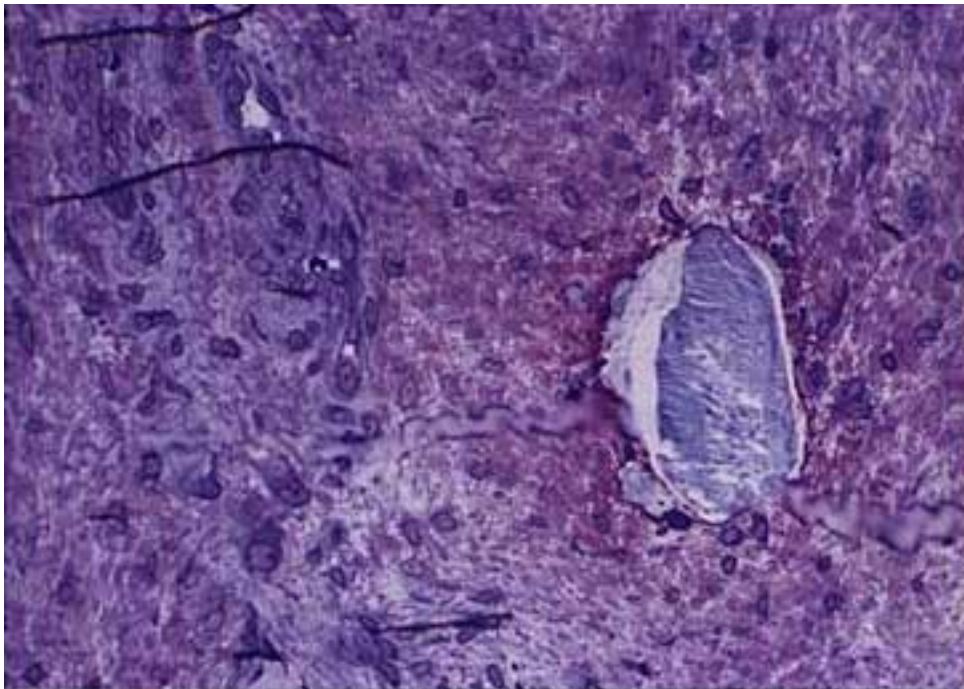


FIG. 7

Photomicrograph demonstrating a crystal that was found within the region of tendinosis in a patient who had had twelve injections of cortisone for the treatment of tennis elbow. The cellularity is plump and pale, with increased cytoplasm; thus, it is mesenchymal in appearance, with randomly oriented dedifferentiated fibroblasts. It has been suggested that, in the damaged tendon, the tenocyte dedifferentiates into a mesenchymal cell, which is capable of changing into vascular, adipose, chondroid, osseous, or fibroblast cell types. The matrix lacks any structural organization (toluidine blue,  $\times 300$ ).

Low-power magnification of sections that had been stained with hematoxylin and eosin revealed the formation of longitudinal clefts between fascicles; the clefts

were sometimes demarcated by fibroblastic hyperplasia, as if these cells had multiplied in response to the local stress of the shearing tears. In addition, there were

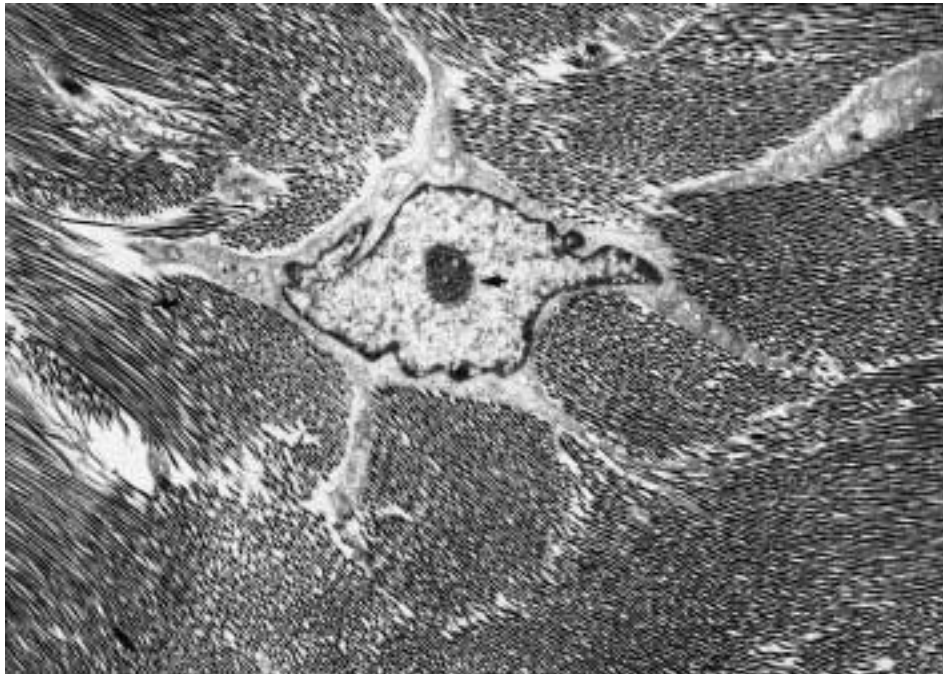


FIG. 8

Electron microscopic image of a normal tenocyte. The stellate cytoplasmic shape with projections into the surrounding matrix is quiescent, lacking evidence of an active production response. The nucleus-to-cytoplasm ratio is high, the nucleus is centralized, and the chromatin is condensed at the center of the nucleus (solid arrow). The collagen matrix has organized bundles of uniformly sized collagen fibrils and lacks debris in the ground substance ( $\times 5130$ ).

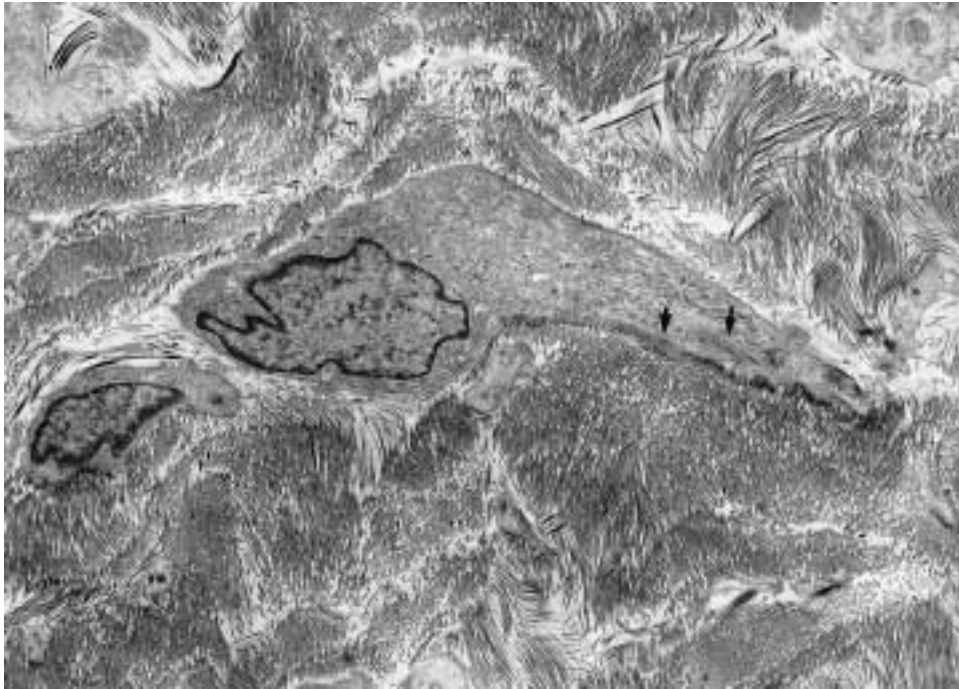

FIG. 9

Electron microscopic image of a myofibroblast from an area of tendinosis. The cell is elongated and lacks stellate projections. The nucleus-to-cytoplasm ratio is small, and the chromatin is not condensed. The nucleus is eccentrically located. The cytoplasm is loaded with mitochondria, endoplasmic reticulum, and vacuoles, presumably for secretion. Pale-gray condensations along the cytoplasmic border are contractile elements (arrows), which may allow cellular movement. The surrounding collagen matrix is disorganized and unreformed, and debris is apparent in the ground substance ( $\times 4275$ ).

whorls of loosely woven, disorganized collagen, typical of tendinosis (Figs. 2 and 3). Masson-trichrome staining of a more severely affected specimen revealed the for-

mation of clefts, permeative collagen disarray, and loss of distinction between the planes of tendon fascicles (Fig. 5). Higher-power magnification of a section that

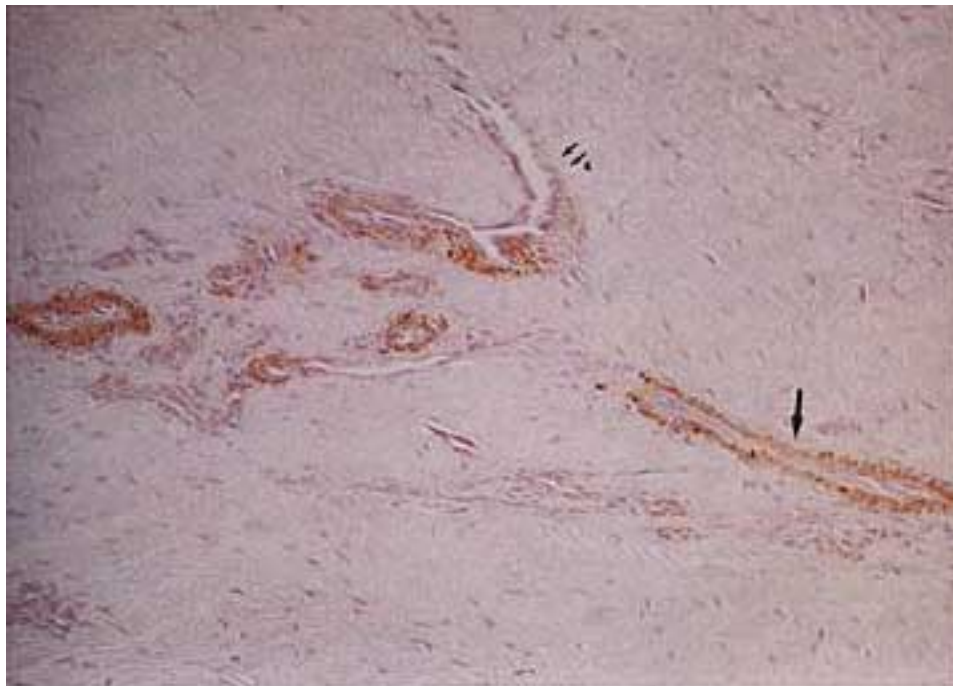


FIG. 10

Photomicrograph demonstrating the vascularity in tendinosis. Parts of the cell-lined lumen contain smooth muscle (single arrow), reflecting maturation into a vascular structure, whereas other areas do not stain (double arrow). It is believed that the tenocytes in injured tendons dedifferentiate into pluripotent mesenchymal cells, leading to local metaplasia (smooth muscle antigen,  $\times 50$ ).

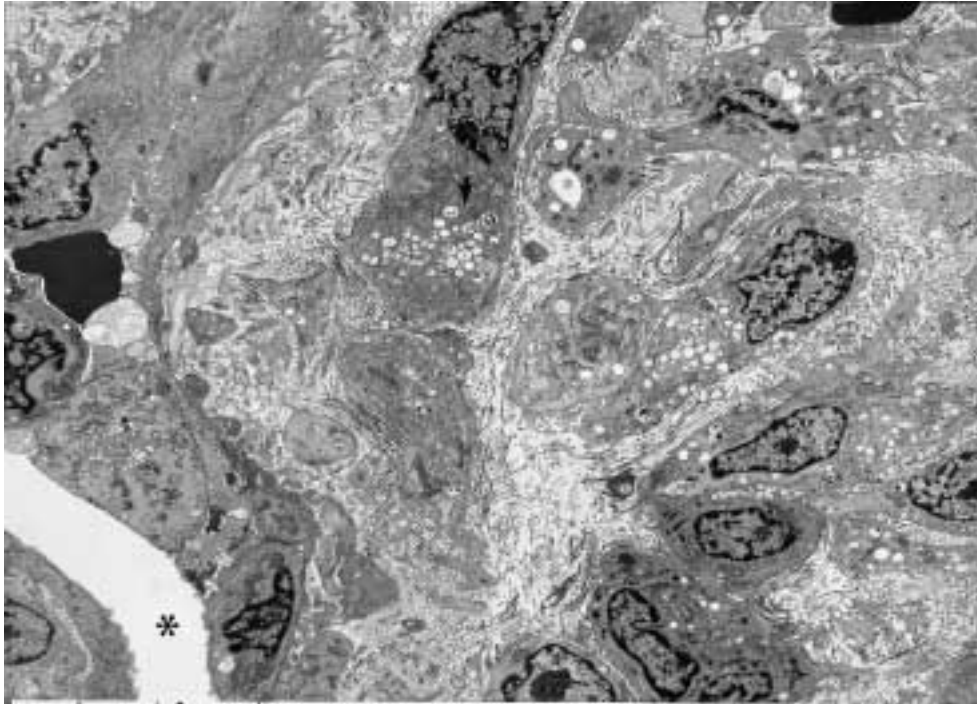


FIG. 11

Electron microscopic image demonstrating the vascular region in an area of tendinosis. Despite the presence of a vessel lumen (asterisk), a dense collection of fibroblasts is seen to contain areas of hypoxic granulation (arrow). The collagen matrix and the ground substance are in disarray and are full of debris. The presence of a vessel lumen does not result in a good remodeling process. It is believed that the vascular channel is formed locally and is not an ingrowth of functioning capillaries ( $\times 3420$ ).

had been stained with vimentin revealed a blend of abnormal and more normal-appearing collagen (Fig. 6), whereas staining for elastin showed nests of tendinosis insinuated between fibers of normal collagen (Fig. 4). In addition, the collagen in areas of tendinosis was both integrated into the surrounding matrix and appeared as a separate mass of unremodeled collagen and matrix production.

The findings of electron microscopy provide an explanation for the abnormal appearance of collagen in tendinosis. Normally, tendon collagen appears to have approximately a sixty-four-nanometer-wide, triple helical, quarter-stagger arrangement. On cross section, normal fibrils appear to be fairly uniform in diameter<sup>19</sup>. In previous studies of tendinosis, several authors have described disintegration of collagen fibrils, longitudinal splitting, abnormal fibril diameters, bubble formation, angulation, and knick deformations (folding of the surface of collagen fibrils, usually in the inner curves of the angulated fibrils)<sup>24,26,27,35,63</sup>.

In the present study, we reviewed only abnormal material obtained from areas of tendinosis. Within the specimens, however, there were normal-appearing regions that served as an internal basis for comparison (Figs. 1 and 13). The longitudinal sections showed uniform fibrils within the normal-appearing collagen. These fibrils were parallel to each other and extended long distances in sheets without gaps. The cross sections showed normal fibrils, with an even mixture of thick

and thin fibrils depending on the presence of fibril cross-linking. The fibroblasts to which the normal collagen appeared to be attached had a high nucleus-to-cytoplasm ratio and contained condensed chromatin within a nucleus containing one centriole. The cytoplasm was sparsely vacuolated. Each cell was stellate with projections into the surrounding collagen matrix (Fig. 8).

In the present study, electron microscopy revealed that the abnormal collagen in the regions of tendinosis was composed of individual strands, which were of normal width and had a normal periodicity of banding pattern. However, the fibrils did not form fascicles and often were highly fragmented into very short segments that were mixed among longer pieces. The background matrix was loose and was filled with what appeared to be debris. On cross section, collagen fibers from the area of tendinosis were of variable diameter, with an uneven mixture of thick and thin fibrils. In the regions of severe tendinosis, collagen fibers did not connect with each other to provide a tendinous structure, and in no instance did such poorly formed material provide evidence of combining with or becoming normal tendon. From a structural perspective, the ultrastructure of collagen in tendinosis is unable to sustain a tensile load (Fig. 14).

#### *Associated Findings*

The cell population in tendinosis consists predominantly of mesenchyme-derived cells, such as fibroblasts

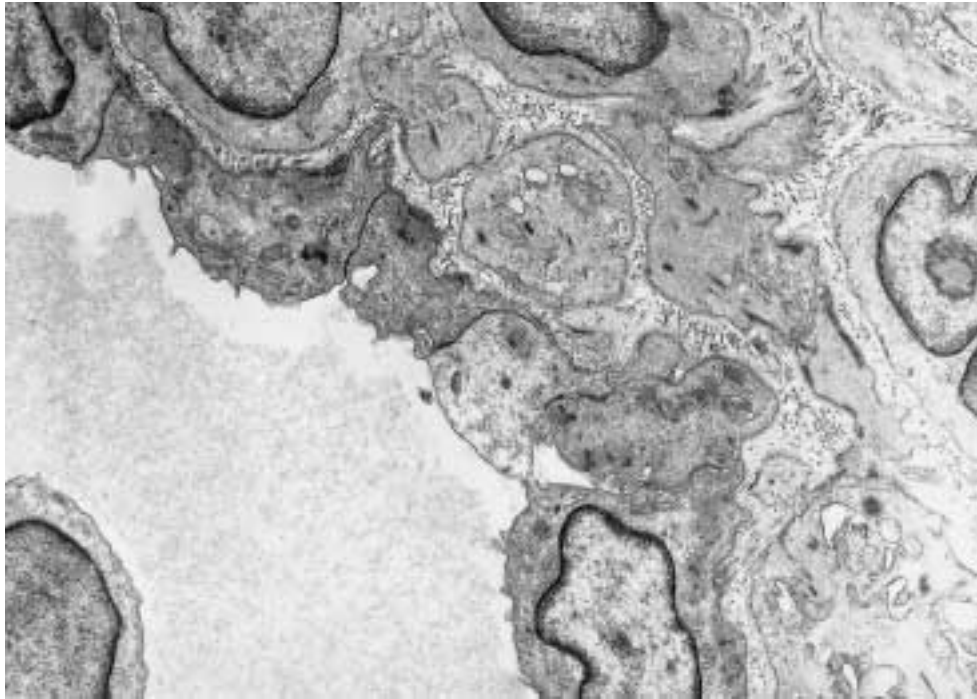


FIG. 12

Electron microscopic image demonstrating a vessel in an area of tendinosis. Vessels were abnormal and contained reduplicated basal lamina and pericytes in multiple layers, a thickened inner lining, and some gaps in the basal lamina ( $\times 8550$ ).

and endothelial cells. Other mesenchyme-derived cells in tendinosis include osteocytes, chondrocytes, pericytes, and adipocytes<sup>27,35,69</sup>. Iwasaki et al.<sup>22</sup> demonstrated that chemical mediators such as tumor growth factor-beta

and bone morphogenic protein can convert periosteal mesenchymal stem cells into chondrocytes and osteocytes, respectively. Thus, it is understandable why regions of calcified and chondroid material as well as fat

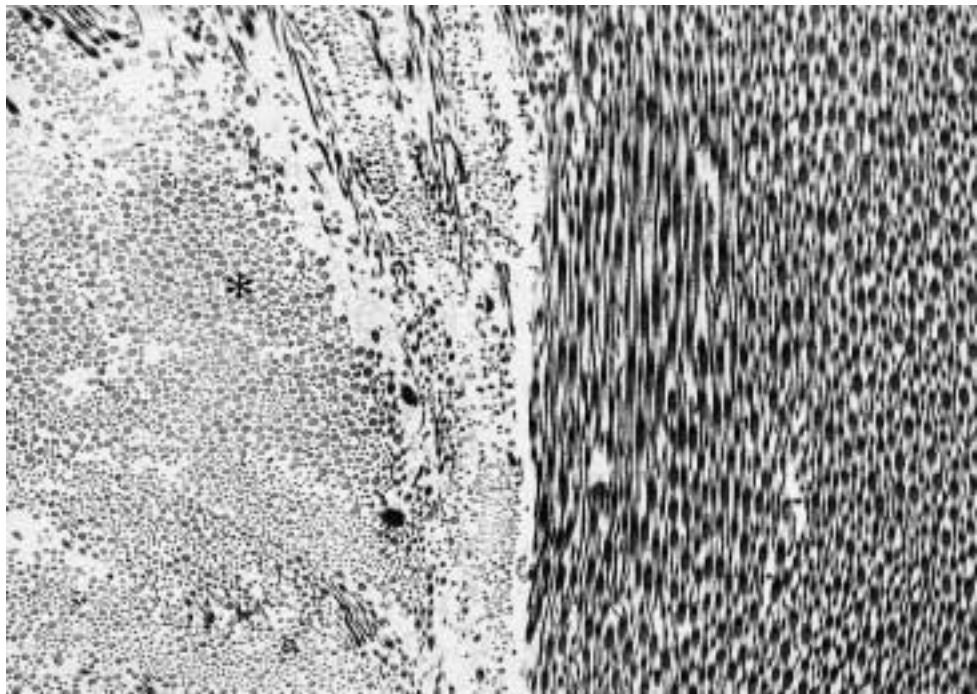


FIG. 13

Electron microscopic image of collagen from a normal-appearing region of tendinosis, demonstrating collagen fibrils with small and large diameters (asterisk). The overall structural arrangement is organized in parallel bundles with no fragmentation and good cross-linkage ( $\times 10,260$ ).

deposits have been reported in areas of tendinosis<sup>27,35,48,68</sup>. In the present study, the presence of fat deposits was confirmed by elastin staining because the counterstain that was used stains fat yellow (Fig. 4). The fat deposits were observed in abnormal-appearing regions, but true adipocytes rarely were seen. Electron microscopy revealed lipid vacuoles within the fibroblasts in the areas of tendinosis (Fig. 11).

In the present study, chondroid regions in the areas of tendinosis were observed on the sections that had been stained with hematoxylin and eosin as well as those that had been stained with toluidine blue. True chondrocytes were observed in some basophilic regions of cartilage, but these regions were not widespread and they blended into the tendon matrix at their margins. It is known that tendons that wrap around convex surfaces are subjected to compressive forces and assume a cartilage-like appearance, presumably by metaplasia<sup>72</sup>.

The generally accepted observation that tendinosis lacks the cellularity that is associated with inflammation is based on the consistent observation that derivatives of the hematopoietic stem cell are not seen in abundance in areas of tendinosis<sup>66</sup>. These cell lines include blood cells such as neutrophils, basophils, eosinophils, plasma cells, and lymphocytes. Related tissue-bound cells include mast cells, megakaryocytes, macrophages, and monocytes. In the present study, macrophages, lymphocytes, and plasma cells occasionally were seen with electron microscopy but certainly not in numbers capable of contributing to the healing process of tendinosis. The occasional presence of inflammatory cells does not explain the presence of pain in areas of tendinosis<sup>35</sup>.

The innervation of tendons normally does not penetrate the fascicles, and we were unable to find any studies on the innervation of tendons in patients who had tendinosis. In the present study, examination of one specimen that had been stained with neurofilament immunostain as well as protein S-100 revealed a small cluster of axons and nerve sheath within the region of angiofibroblastic hyperplasia. This finding is not considered to be confirmation that areas of tendinosis are innervated with nociceptive fibers, but this should be studied further. We suspect that the cause of pain in tendinosis is chemical irritation due to regional anoxia and the lack of phagocytic cells to remove noxious products of cellular activity, such as lactic acid<sup>35</sup>.

Previous investigators have reported calcification, hemorrhage, fibrinoid degeneration, and crystalline debris in the matrix<sup>48,59</sup>. We found similar changes in the present study. In addition, we found a crystal of foreign material in a specimen from one patient who had had twelve injections of cortisone (Fig. 7). We view these changes as secondary developments that are associated with tendinosis. The essential pathological finding is angiofibroblastic hyperplasia.

#### *Pathophysiology: Clinical Correlation*

The three fundamental elements of tendinosis of the elbow are fibroblastic hyperplasia, vascular hyperplasia, and abnormal collagen production. Repetitive overuse or a traumatic injury creates fibroblastic hyperplasia, which is the initial response in tendinosis. Shear forces within the tendon may either signal the mechanoreceptors (integrins) on the surface of the resting tenocyte or

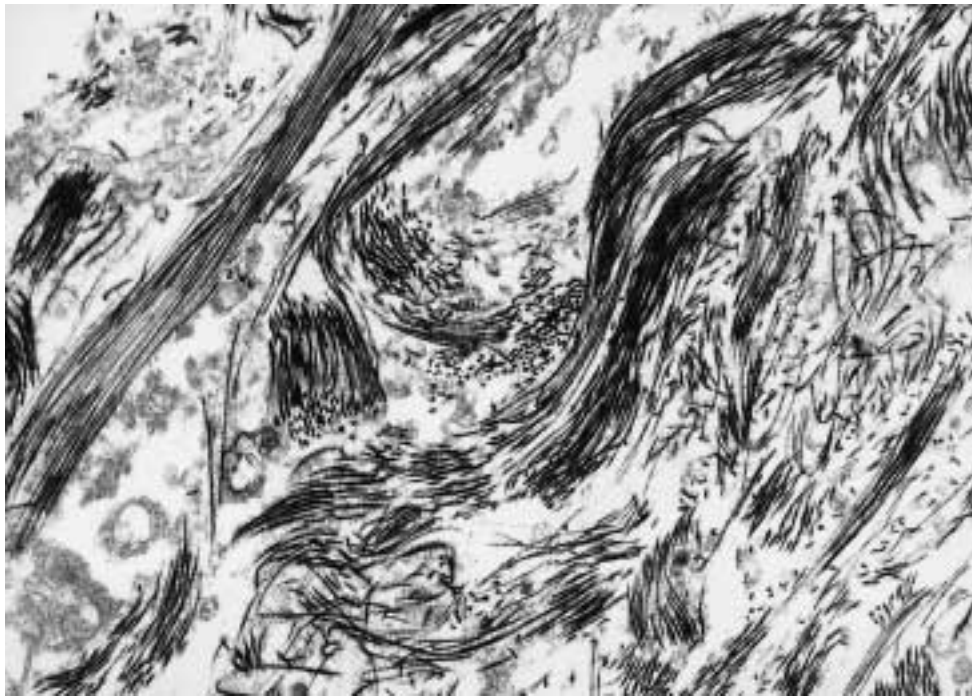


FIG. 14

Electron microscopic image demonstrating short fragments of collagen that completely lack structural organization ( $\times 13,690$ ).

actually harm the cells when a cleavage plane is formed between the tendon fascicles. The activated fibroblast begins to multiply and starts to produce collagen locally<sup>45,46</sup>. Some fibroblasts return to their mesenchymal state, whereas others develop chemotactic mobility and intracellular contractile elements. Dedifferentiated fibroblasts may form cartilage cells, bone-forming cells, and vascular endothelium<sup>17,69</sup>. This process represents the intrinsic capacity of tendons to attempt to heal. It does not preclude the potential contribution of an extrinsic source of fibroblasts in tendinosis, but we suspect that it is the lack of an effective vascular system that leads to the failure of the healing cycle in tendinosis<sup>45,58</sup>. Instead of a humoral process being guided by the immune-based inflammatory response, the mesenchymal cell-based process in tendinosis lacks the chemical guidance that normally would lead to maintenance of the matrix and the expected remodeling phase of tendon-healing.

The abnormal vessels in tendinosis may be dedifferentiated fibroblasts that became mesenchymal cells and then endothelial cells. The presence of surrounding fibroblasts could be either an influx of extrinsic cells or a local microenvironmental population of reprogrammed cells in an active fibroblast milieu. When one considers the thick, abnormal basement membrane and the constricted appearance of vessels found in tendinosis, one cannot presume that such abnormal vessels could be an effective source of extrinsic fibroblasts. Rather, the pluripotent tendon fibroblast may use local chemical mediators, which it is capable of manufacturing, to form rudimentary blood vessels. Chemical modifiers of cellular activity are known to be mitomorphogenic. For example, in one *in vitro* study of periosteal-derived cells, fibroblast growth factor-beta (FGF- $\beta$ ) stimulated the proliferation of fibroblast-like cells but inhibited osteochondrogenic differentiation<sup>22</sup>. Mitogens such as platelet-derived growth factor-beta (PDGF- $\beta$ ) induce fibroblastic mitosis, and chemotactic polypeptides such as tumor growth factor-beta (TGF- $\beta$ ) cause fibroblasts to migrate and specialize and have been found to cause angiogenesis<sup>18</sup>.

The presence of red blood cells inside the abnormal vessels found in regions of tendinosis suggests that vascular hyperplasia may lead to communication with an extrinsic healing response, provided that the immune system receives signals of a need for the healing process. We suspect that rehabilitation exercise stimulates regional hyperemia. Controlled exercise is likely to deliver cyclical tensile loads that stimulate the remodeling of collagen. Rehabilitation exercises that are designed for patients who have tendinosis of the elbow should focus on the creation of low-impact repetitive tensile forces across the collagen matrix-fibroblast system that is the essence of tendon as a structure. Fibroblasts in tendinosis are extremely active metabolically. The capacity for the production of collagen is abundant, although in the

present study we did not attempt to determine whether the collagen in tendinosis is primarily type I or type III; both types have the same ultrastructural appearance, with a sixty-four-nanometer periodicity and a quarter-stagger arrangement of filaments. We suspect that it is the extracellular alignment and cross-linking of collagen that fails in tendinosis<sup>18,39</sup>. This fibroblast-driven process normally would be expected to integrate old and new collagen in order to contribute to the final stability of the matrix<sup>18,71</sup>.

Majamaa<sup>37</sup> was able to delay the formation of the collagen triple helix chemically, and Gelberman et al.<sup>18</sup> found that the metals zinc and cobalt inhibit the production of collagen. It was beyond the scope of the present study to identify whether the abnormality of collagen in tendinosis is due to faulty production of procollagen within the fibroblast; the lack of cleavage of the hydroxyl, amino, and carboxyl groups extracellularly; or the inhibition of cross-linking in the extracellular matrix by a toxic chemical environment. Because all of the patients in the present study had received injections of cortisone before operative intervention (average, four injections; range, one to twelve injections), it is impossible to know whether cortisone contributed to the collagen disorder; nevertheless, identical findings have been reported in studies of patients who had not received injections of cortisone<sup>6,8,18,26-28,35,45,57,59</sup>. Like Regan et al.<sup>59</sup>, we cannot comment on whether inflammatory cells would have been absent if injections of corticosteroids had not been used. Our anecdotal experience has been that the histopathological process in tendinosis is unrelated to the use of corticosteroids<sup>26,59</sup>. It would be useful to perform a similar study of patients who have not received injections of cortisone. Studies of normal tendons that have been injected with corticosteroids have demonstrated disruption of collagen fibers, infiltration by lymphocytes, the presence of lipid-laden histiocytes, and impairment of fibroblastic proliferation and matrix formation, findings that are not characteristic of tendinosis<sup>5,6,59</sup>.

In order to understand the details of failed and normal tendon-healing processes, it would be valuable to study the control system that guides the cellular activity of tendon fibroblasts. Future studies focusing on the chemical signals that result in the structural abnormalities described in the present report are of potentially great value because they may lead to the chemical control of tendinosis. While we do not believe that cortisone is the correct chemical for this purpose, we envision a specific injection that would bathe the affected area with beneficial material. The cause of pain in tendinosis may be related to the chemical characteristics of the matrix (including the pH level, the level of lactic acid, and the level of prostaglandins). It would be valuable to identify the chemical signals for tendon maturation and the type of collagen (type I or III) produced in tendinosis, for the knowledge gained also may explain

tendinous pain in other locations as well as the chemical events associated with the use of ligaments as autologous grafts<sup>18,32,41,45</sup>.

### Materials and Methods

In order to study the architecture, composition, and ultrastructure of tendinosis more closely, intraoperative specimens from nine patients (nine elbows) who had tendinosis of the elbow were analyzed histologically and compared with specimens from ten cadavera. Hematoxylin and eosin was used for the initial observations, and additional information was obtained with use of special stains, immunohistochemical analysis, and electron microscopy.

All nine patients initially were managed with non-operative treatment, including physical therapy exercises designed to strengthen the extensors of the wrist and fingers. The average age of the patients at the time of the operation was forty-five years (range, thirty-eight to fifty-one years). The average duration of preoperative treatment was three years (range, one year and six months to five years). The preoperative treatment modalities included high-voltage electrical stimulation, heat and ice treatments, and injections of corticosteroids, most of which had been administered elsewhere. The patients had had an average of four injections (range, one to twelve injections) of steroids. None of the patients had had previous operative treatment.

The operation was performed according to the method described by one of us (R. P. N.) for lateral tendinosis of the elbow<sup>48</sup>. The gross appearance (color and consistency) of the resected specimen was noted, and the specimen then was divided through the most degenerative region. One-half of each sample was immediately fixed in 10 percent formalin, and the other half was fixed in 2 percent glutaraldehyde. The specimens that had been fixed in formalin were embedded in paraffin and sectioned in a routine fashion. Hematoxylin and eosin was used to survey the cellularity and general architecture of the specimen as well as the appearance of the matrix. This stain also was used as a tool to screen for tendinosis in the cadaveric specimens. Modified Verhoeff-van Gieson (elastin) stain was used as a stain for vascular elements, as a counterstain for fat deposits, and as a gauge of elastin content. Masson trichrome stain (Sigma Diagnostics, St. Louis, Missouri) containing nuclear, collagenous, and cytoplasmic agents was used to assess collagen as well as cellular elements. Immunohistochemical stains (Calbiochem, Cambridge, Massachusetts) also were used. Specifically, vascular elements were visualized with Factor 8 and smooth muscle antigen (SMA) counterstains affixed to a carrier containing a silver-based stain, fibroblasts were visualized with vimentin stain, and neural elements such as the nerve sheath and the axons were studied with protein S-100 and neurofilament stain, respectively. Toluidine blue, which stains cartilaginous tissues, also was

used to identify regions of pathological interest in the seven operative specimens that were examined with a transmission electron microscope (model 100-S; Jeol, Peabody, Massachusetts). The specimens that had been fixed in glutaraldehyde were double-fixed in osmium tetroxide and embedded in Epon resin. Ten-nanometer-thick sections were obtained with use of an ultramicrotome and were stained with uranyl acetate and lead citrate for electron microscopy.

Control specimens were obtained from the extensor carpi radialis tendon of ten cadavera. The specimens were preserved with formalin, embedded in paraffin, and stained with hematoxylin and eosin. Because no evidence of tendinosis was observed in these specimens, and because the histological appearance of normal tendon has been well documented, these specimens were not subjected to immunohistochemical analysis or electron microscopy. Some of the operative specimens contained normal-appearing regions, which were compared with the pathological areas.

Transmission electron microscopy was used to trace the maturation of collagen fibers more closely on the basis of the periodicity of collagen strands. Electron microscopy also revealed that myofibroblasts are present in tendinosis; these cells have contractile properties and are not usually found in healthy tendons. The relationship between fibroblasts and the surrounding collagen strands in areas of tendinosis was found to differ from that in normal tendon.

The characteristics of the tissue removed from the site of pain in our patients who had tennis elbow were consistent with tendinosis. The new findings of the present study include qualitative observations of the overall appearance of tendinosis at a low level of magnification. Staining with hematoxylin and eosin demonstrated the confluence of abnormal and normal regions in the context of the appearance of the entire tendon. The modified Verhoeff-van Gieson (elastin) stain demonstrated the appearance of a contained localized response, but the Masson trichrome and vimentin stains showed evidence of a permeative response throughout the tendon. These findings are related to current concepts regarding the physiological response of tendon to injury.

The findings of the present study confirm what we believe to be the essential elements of tendinosis — namely, that inflammatory cells are conspicuously absent and that mesenchymal differentiation and metaplasia are the primary cellular events. Staining with toluidine blue confirmed the presence of mesenchymal cells. Whereas Sarkar and Uthoff<sup>53</sup> observed myofibroblasts near vessels, we observed such cells both close to and at a distance from vessels. This finding raises the question of whether tendinosis is an invasive or a local process.

We observed inconsistent staining patterns when elastin and smooth muscle antigen stains were used to evaluate the vessels within the region of tendinosis. We interpret this finding to mean that the vessels in

tendinosis are in varying stages of maturation. Although it was not possible to determine whether such vessels were in the process of maturing further or were in a stage of arrested maturation, electron microscopy revealed that the ultrastructural properties of the lumen, basal lamina, pericytes, and surrounding matrix remained abnormal. In addition to confirming the findings of Sarkar and Uthoff<sup>83</sup> as well as those of Kannus and Józsa<sup>27</sup>, we found multiple layers of pericytes, some of which contained contractile elements.

We also observed that the presence of vascular channels is not associated with any improvement in the quality of the local tissue. In contrast to previous authors, we could not identify any vessels with evidence of blood flow. Light microscopy did not reveal any organized pattern of connectivity of blood vessels or the presence of erythrocytes within vascular channels despite the presence of smooth muscle and elastin in the vessel walls. These findings suggest that the vascular hyperplasia in tendinosis is consistent with local metaplasia rather than capillary ingrowth.

The presence of elastin and smooth muscle in the vessel walls supports the hypothesis that the tissue in areas of tendinosis is not purely degenerative but rather may be in varying stages of repair and maturation. It is possible that failure to improve with nonoperative treatment reflects an arrested state of healing or a futile response resulting from a lack of communication with the humoral immune system.

Our observations of the collagen in tendinosis are qualitative. Sarkar and Uthoff<sup>83</sup> as well as Kannus and Józsa<sup>27</sup> previously described their findings on electron microscopy. Our electron microscopic findings perhaps better demonstrate the differences between normal collagen and collagen in tendinosis. We confirm that the individual fibrils are not entirely normal in cross-sectional diameter (alternating between thick and thin), but we emphasize that the most striking structural abnormality is the lack of extracellular cross-linkage and the complete disarray of the matrix with evidence of debris. The Masson trichrome stain demonstrated the permeative extent of abnormal collagen production in tendinosis, a qualitative finding that supports the belief that tendinosis is a connective-tissue disease that involves the production of collagen that is not remodeled into normal tendon before operative treatment.

### Treatment Considerations

#### Principles of Treatment

The biological goals of the treatment of tendinosis are to obtain viable neural elements as well as normal vascularization and collagen production to promote healing. This is in contradistinction to the more common treatment protocols, which include the use of anti-inflammatory medications, local injections, and prolonged physical therapy. A detailed monograph of contemporary nonoperative treatment techniques was

recently written by one of us (R. P. N.) and Sobel<sup>49</sup>.

The primary goals of the treatment of tendinosis are the control of pain; the preservation of motion, flexibility, and strength; and the development of endurance over time. Although there is no evidence to suggest that anti-inflammatory medications actually promote healing, the lack of an appropriate (resistance-based) rehabilitative exercise program ensures the failure of healing<sup>45</sup>. Nonsteroidal medications are effective for the control of pain as long-acting analgesics. We do not routinely use injections of cortisone in the treatment of tennis elbow; however, we occasionally have used one injection of cortisone for patients who are unable to perform rehabilitative exercises because of pain. Operative treatment, which is reserved for patients who fail to respond to a well structured program of rehabilitation, is intended to revitalize, debride, and bypass the area of tendinosis<sup>10,44,45,65,66</sup>.

#### Control of Pain and Inflammation

In the acute setting, pain related to tendinosis of the elbow (or another structure) is controlled by protection from abuse, relative rest, application of ice, compression, elevation, medication, and passive modalities such as ultrasound, electrical stimulation, phonophoresis, massage, and so on. Nonsteroidal anti-inflammatory drugs currently are the medication of choice, although it has not been proved that these agents have a specific effect on fibroblast function or tendon-healing<sup>43,66</sup>. Almekinders et al.<sup>2</sup> performed an *in vitro* study of the effect of indomethacin on human fibroblasts. After repetitive tissue-stretching, PGE<sub>2</sub> (prostaglandin E<sub>2</sub>) was secreted by fibroblast cells; the presence of macrophages increased the secretion of PGE<sub>2</sub>. Those authors found that indomethacin inhibited the secretion of PGE<sub>2</sub>, a beneficial effect; however, it also inhibited the synthesis of DNA, an effect that might be detrimental to the proliferative phase of repair. Indomethacin increased protein synthesis by fibroblasts, potentially benefiting the remodeling phase of repair. In the present study, we did not examine the effect of anti-inflammatory medications on the physical structure of collagen. As the histological images show, it is not only the presence of collagen but also its structural arrangement that determines the quality of tendon. We know of no medication or anti-inflammatory agent of any kind that has been proved to have a beneficial effect on the mechanical and material properties of tendon. Orally administered anti-inflammatory medications may remain beneficial not only as analgesics but also as inhibitors of inflammation (myositis and tendinitis) in surrounding regions. This will make it easier to rehabilitate injured muscle-tendon groups as well as the muscles in the surrounding kinetic chain. It is hoped that with the use of cyclooxygenase-2-specific inhibitors of inflammation, it may become possible to control pain with fewer side effects.

The injection of corticosteroids is a form of treat-



ment that can be used to decrease the pain at the site of tendinosis at least temporarily. While many orthopaedic surgeons think that injections of cortisone are safe and effective, Almekinders<sup>3</sup>, in a review of the literature, found that only three of eight controlled studies demonstrated that such treatment had long-term efficacy. Those authors found numerous other articles in which intratendinous injections of corticosteroids were associated with deleterious effects, including tendon rupture.

Stahl and Kaufman<sup>64</sup>, in a prospective, randomized study of sixty elbows, investigated the treatment of medial epicondylitis with a single injection of either lidocaine and cortisone or lidocaine and saline solution. Those authors found that a single injection of cortisone was associated with a reduction of pain at six weeks; however, at three months and at one year, the cortisone had no beneficial effect compared with the placebo. Leadbetter<sup>34</sup> reviewed the literature on the use of injections of corticosteroids for the treatment of sports-related injuries and concluded that such treatment should remain a form of adjunctive therapy and not the sole means of treatment. We prescribe injections of corticosteroids only on the rare occasion when the pain is so severe that it prevents the patient from performing rehabilitative exercises.

#### *Promotion of Healing*

Although the use of local injections increases the risks of disrupting tissue planes, creating high-pressure tissue necrosis, and rupturing the tendon, fenestration of the area of tendinosis may be beneficial because of the bleeding that occurs in the new channels that are created through degenerated, myxoid tissue. The mechanical disruption may transform a failed intrinsic healing process into an extrinsic response; this may be the reason that injections of steroids occasionally have fortuitous, lasting benefits. Injections of cortisone remain a risky modality and are not a proved cure for tendon injuries. In order to have curative potential, any chemical that is injected into or around a tendon must alter the pathological process in tendinosis. Hildebrand et al.<sup>21</sup> reported that the administration of platelet-derived growth factor-BB directly onto the freshly torn medial collateral ligaments of rabbits improved the mechanical properties of ligamentous tissue in the early phase of healing. Histologically, this growth factor caused fibroblastic hyperplasia and vascular formations, features also seen in tendinosis. Those authors noted that the specific platelet-derived growth factor induced the expression of tumor growth factor-beta but did not find that adding transforming growth factor-beta to the treatment had any beneficial effect. It is possible that a specific chemical that mediates growth in the natural healing cascade will prove beneficial in the treatment of tendinosis.

Even if a chemical agent that can alter the failed healing process is developed, it is unlikely that the

chemical itself will fully restore the functional quality of the tendon, which is dependent on the forces that are delivered to that structure. It is well known that complete immobilization weakens a tendon. Yamamoto et al.<sup>73</sup> reported a decrease of approximately 84 percent in the tensile modulus of the patellar ligaments of rabbits after six weeks of stress-shielding with a wire shunt. Saltzman and Tearse<sup>61</sup> noted that the diameter of the Achilles tendon thickens in response to exercise and atrophies in response to immobilization. Within physiological limits, the tensile strength and stiffness of tendon increase with continuous repeated loading<sup>49,61</sup>. O'Brien<sup>51</sup> reported that when a tendon is immobilized after an injury, it can lose as much as 40 percent of its ground substance. Early motion helps to align the collagen fibers, thereby improving tensile strength. Thus, the promotion of tendon-healing depends on exercise of the injured region with use of a controlled program of rehabilitation. Initially, the patient is advised to decrease the level of activity with use of pain as the limiting factor but without immobilizing the injured part completely. A counterforce tennis-elbow brace may be used for the treatment of tendinosis of the elbow, but we do not routinely apply a splint or a cast to immobilize the wrist or the elbow. The mainstay of nonoperative treatment of tendinosis of the elbow is a resistance-based exercise program that is advanced in concordance with the ability of the patient to participate in the program. Therefore, the initial phases of the rehabilitation program should be supervised by a therapist who understands the rationale underlying the treatment.

After a brief period of relative rest, the patient begins concentric exercises, initially with use of low resistance; the number of repetitions and the intensity of resistance then are gradually increased. Although the high forces of eccentric muscle activation are believed to be responsible for tendon failure, some authors believe that eccentric forces are beneficial in the more advanced phases of strengthening<sup>23</sup>. Alfredson et al.<sup>1</sup>, in a prospective study of fifteen athletes who had tendinitis of the Achilles tendon, reported that an exercise protocol based purely on eccentric loading allowed all subjects to return to their preinjury level of sports activity within three months without operative intervention. The exercise protocol involved the application of gradually increasing resistance, and the exercises always were performed at a slow velocity. In contrast to traumatic events, which produce rapid eccentric forces, low-velocity eccentric loading presumably does not exceed the elastic limit of the tendon and generates less injurious heat within the tendon.

Strength, flexibility, and endurance are the three essential elements of musculotendinous rehabilitation. Flexibility is achieved through a disciplined stretching program that may be instituted early in the course of treatment. Endurance is developed over time as the patient becomes able to tolerate more repetitions and

sustained activities. If endurance is not developed and the muscle-tendon unit becomes fatigued, the muscular portion can no longer absorb the stresses and greater stresses are absorbed by the tendon<sup>71</sup>.

Kibler et al.<sup>29-31</sup> as well as one of us (R. P. N.) and Sobel<sup>49</sup> outlined many of the more subtle elements of rehabilitation after tendon injury in competitive athletes. The rehabilitation program described by Kibler et al. includes a program to increase the strength in opposing muscles, such as the flexors of the wrist and digits, in order to balance the force couple. Because pain causes neuromuscular deconditioning, the rehabilitation program also must address the altered proprioceptive feedback. This requires the use of neuromuscular feedback and feedforward techniques to restore the reflexive speed and accuracy of the entire kinetic chain.

#### *General Fitness*

In order to adapt to weakness of the muscles of the shoulder, a tennis player will attempt to generate force with the muscles of the forearm, thereby predisposing to tendinosis of the elbow. The application of kinetic-chain exercises to the treatment of tendinosis of the elbow involves strengthening of the muscles of the rotator cuff and those around the scapula. During a tennis swing or serve, the ground-reaction force, body-weight transfer, and rotational forces about the trunk must pass energy through the scapulothoracic and rotator-cuff muscles. The same is true during throwing motions used in other sports. Weakness of the muscles about the shoulder, especially the external rotators, must be treated in patients who have sustained tendinosis of the elbow while participating in racquet or throwing sports<sup>31,49</sup>. General fitness and endurance are valuable when an athlete returns to competitive sports because fatigue can lead to alterations in efficient techniques of play, thereby making the individual susceptible to injury at various vulnerable sites. Aerobic conditioning is especially valuable for those who participate in sports involving endurance<sup>31</sup>.

#### *Controlling Abuse and Force Loads*

Athletes instinctively modify their techniques of play to avoid motions across painful, injured tissues. Such adaptations not only serve as warning signs of the severity of injury but also function as a defensive strategy to prevent further abuse of the overused tissues. Unfortunately, when pain alters an athlete's technique, the individual may not be able to make adjustments that sufficiently protect the injured tendon. Continued abusive sports activity has two detrimental microscopic consequences: increased matrix degeneration and inadequate matrix synthesis<sup>34,50</sup>. Thus, tendon overuse causes tendinosis.

In an attempt to determine the clinical relevance of the severity of pain, the senior one of us (R. P. N.), on the basis of his extensive experience in the treatment of

tennis-elbow tendinosis, described seven phases of pain. Although there is no histological correlation for each phase, the conceptual association of the severity of symptoms with the presumed degree of tissue damage is helpful in directing treatment. This information was previously published in the form of a table<sup>49</sup>.

*Phases 1 and 2. Benign (nonharmful) pain:* Phase-1 pain is characterized by stiffness or mild soreness after activity and resolves within twenty-four hours. Phase-2 pain is marked by stiffness or mild soreness after exercise, lasts more than forty-eight hours, is relieved with warm-up exercises, is not present during activity, and resolves within seventy-two hours after the cessation of activity. Phase-1 and 2 pain may be due to peritendinous inflammation.

*Phase 3. Semibenign (likely nonharmful) pain:* Phase-3 pain is characterized by stiffness or mild soreness before activity and is partially relieved with warm-up exercises. The pain does not prevent participation in activity and is mild during activity. However, counterforce bracing and minor adjustments in the technique, intensity, and duration of activity are needed to control the pain. Phase-3 pain may necessitate the use of nonsteroidal anti-inflammatory medications.

*Phase 4. Semiharmful pain:* Phase-4 pain is more intense than phase-3 pain and produces changes in the performance of a specific sports or work-related activity. Mild pain accompanies the activities of daily living. Phase-4 pain may reflect tendon damage.

*Phases 5, 6, and 7. Harmful pain:* Phase-5 pain, which is characterized by moderate or severe pain before, during, and after exercise, greatly alters or prevents performance of the activity. Pain accompanies but does not prevent the performance of activities of daily living. Complete rest controls the pain. Phase-5 pain reflects permanent tendon damage. Phase-6 pain, which is similar to phase-5 pain, prevents the performance of activities of daily living and persists despite complete rest. Phase-7 pain is a consistent, aching pain that intensifies with activity and that regularly interrupts sleep.

In phases 1 and 2, the pain is usually self-limiting when proper precautions are taken. In phases 3 and 4, the pain usually responds to nonoperative medical therapy. In phases 5, 6, and 7, the pain is more likely to necessitate operative treatment<sup>49</sup>.

In the earlier phases of pain, modification of activity may involve alternating between low and high-intensity workouts<sup>31,34</sup>. Modifications in the type of equipment that is used may control overuse; currently, the use of a midsized medium-flex, graphite tennis racquet with loosely strung nylon monofilament is recommended. The grip size should not be too small<sup>49</sup>. The use of a sports brace (such as the Count-R-Force brace [Medical Sports, Arlington, Virginia]) has been shown to have a beneficial effect on the force-couple imbalances and altered movements associated with tennis elbow<sup>29</sup>.

Throughout all phases of rehabilitation and exer-

cise, training should be within physiological limits for cellular response and homeostasis<sup>50</sup>. Therefore, relative rest is advised during painful periods. The once-popular phrase "no pain, no gain" is no longer acceptable. There should be a gradual transition back to sports activities and other strenuous activities of daily living depending on the recovery of the involved tissues and on the restoration of the athletic skills required to perform the activity. Abusive sports techniques, such as a late backhand in tennis, should be corrected<sup>34,43,46</sup>.

### Operative Treatment

The need for operative intervention can vary widely, depending on the patient's quality of life and the patient mix of the individual surgeon. In the experience of the senior one of us (R. P. N.) with a highly complex referral population, approximately 25 percent (1000) of 4000 patients were managed operatively over a period of thirty years. We estimate that in a general orthopaedic practice less than 5 percent of patients would need operative intervention. We use the previously described pain scale to aid in decision-making. All patients attempt to complete at least three months of a resistance-based rehabilitation program in conjunction with the use of a tennis-elbow brace and oral administration of anti-inflammatory medications. Failure to decrease the pain to a tolerable level may result in operative intervention.

We have observed that a simple handshake test helps to determine which patients are likely to respond to nonoperative treatment. The patient performs a firm handshake with the elbow extended and then supinates the forearm against resistance. The examiner notes whether the patient reports having pain at the origin of the extensors of the wrist. The elbow is then flexed to

90 degrees, and the same maneuver is performed. If pain is decreased in the flexed position, operative treatment is less likely to be needed. If the pain is equally severe with the elbow flexed and extended, then operative intervention is more likely to be needed<sup>33</sup>.

The goals of operative treatment of tendinosis of the elbow are to resect pathological material, to stimulate neurovascularization by producing focused local bleeding, and to create a healthy scar while doing the least possible structural damage to surrounding tissues. The technique described by the senior one of us (R. P. N.) for the treatment of lateral tendinosis of the elbow led to a successful outcome in eighty-eight properly selected patients<sup>48</sup>. That author's technique for the treatment of medial tendinosis of the elbow is based on the same operative principles and has been associated with a similar rate of success. It should be noted that decompression of the ulnar nerve may be an important adjuvant intervention in association with operative treatment of medial tendinosis of the elbow<sup>47,52</sup>. We do not advocate a slide-release procedure or epicondyloplasty because, although these techniques may create a beneficial bleeding response, they do not primarily address the problem of tendinosis. Indeed, in our experience, salvage procedures have been almost exclusively related to a failure to address the pathoanatomy of tendinosis<sup>53</sup>. Postoperatively, we recommend a carefully guided resistance-based rehabilitation program designed on the basis of the previously described principles.

NOTE: The authors thank E. Russell Stay, M.D., of the Department of Pathology at Arlington Hospital for early (1979) descriptions of the histopathological characteristics of tendinosis and for his continuing advice and counsel concerning this project. They also thank Eileen Rusnock at Georgetown University Medical Center for her valuable contributions with respect to the microscopy and electron microscopy.

### References

1. **Alfredson, H.; Pietila, T.; Jonsson, P.; and Lorentzon, R.:** Heavy-load eccentric calf muscle training for the treatment of chronic Achilles tendinosis. *Am. J. Sports Med.*, 26: 360-366, 1998.
2. **Almekinders, L. C.; Baynes, A. J.; and Bracey, L. W.:** An in vitro investigation into the effects of repetitive motion and nonsteroidal antiinflammatory medication on human tendon fibroblasts. *Am. J. Sports Med.*, 23: 119-123, 1995.
3. **Almekinders, L. C.:** Tendinitis and other chronic tendinopathies. *J. Am. Acad. Orthop. Surgeons*, 6: 157-164, 1998.
4. **Amadio, P. C.:** Tendon and ligament. In *Wound Healing: Biomechanical and Clinical Aspects*, pp. 384-395. Edited by I. K. Cohen, R. F. Diegelman, and W. J. Lindblad. Philadelphia, W. B. Saunders, 1992.
5. **Balasubramaniam, P., and Prathap, K.:** The effect of injection of hydrocortisone into rabbit calcaneal tendons. *J. Bone and Joint Surg.*, 54-B(4): 729-734, 1972.
6. **Buckwalter, J. A.:** Current concepts review. Pharmacological treatment of soft-tissue injuries. *J. Bone and Joint Surg.*, 77-A: 1902-1914, Dec. 1995.
7. **Clancy, W. G., Jr.; Neidhart, D.; and Brand, R. L.:** Achilles tendonitis in runners: a report of five cases. *Am. J. Sports Med.*, 4: 46-57, 1976.
8. **Clancy, W. G., Jr.:** Tendon trauma and overuse injuries. In *Sports-Induced Inflammation: Clinical and Basic Science Concepts*, pp. 609-618. Edited by W. B. Leadbetter, J. A. Buckwalter, and S. L. Gordon. Park Ridge, Illinois, American Academy of Orthopaedic Surgeons, 1990.
9. **Coonrad, R. W., and Hooper, W. R.:** Tennis elbow: its course, natural history, conservative and surgical management. *J. Bone and Joint Surg.*, 55-A: 1177-1182, Sept. 1973.
10. **Curwin, S., and Stanish, W. D.:** *Tendinitis, Its Etiology and Treatment*. Lexington, Massachusetts, Collamore Press, 1984.
11. **Cyriax, J. H.:** The pathology and treatment of tennis elbow. *J. Bone and Joint Surg.*, 18: 921-940, Oct. 1936.
12. **Dye, S. F., and Chew, M. H.:** Instructional Course Lecture, American Academy of Orthopaedic Surgeons. The use of scintigraphy to detect increased osseous metabolic activity about the knee. *J. Bone and Joint Surg.*, 75-A: 1388-1406, Sept. 1993.
13. **Eyre, D. R.; Paz, M. A.; and Gallop, P. M.:** Cross-linking in collagen and elastin. *Ann. Rev. Biochem.*, 53: 717-748, 1984.
14. **Forrester, J. C.; Zederfeldt, B. H.; Hayes, T. L.; and Hunt, T. K.:** Wolff's law in relation to the healing skin wound. *J. Trauma*, 10: 770-779, 1970.
15. **Frank, C. B., and Hart, D. A.:** Cellular response to loading. In *Sports-Induced Inflammation: Clinical and Basic Science Concepts*,

- pp. 555-564. Edited by W. B. Leadbetter, J. A. Buckwalter, and S. L. Gordon. Park Ridge, Illinois, American Academy of Orthopaedic Surgeons, 1990.
16. **Gamble, J. G.:** The musculoskeletal system: physiologic basics. In *Athletic Training and Sports Medicine*, edited by L. Y. Hunter-Griffin. Ed. 2, p. 105. New York, Raven Press, 1988.
  17. **Gartner, L. P., and Hiatt, J. L.** [editors]: Connective tissue. In *Color Atlas of Histology*. Ed. 2, pp. 42-57. Baltimore, Williams and Wilkins, 1994.
  18. **Gelberman, R.; Goldberg, V.; An, K.-N.; and Banes, A.:** Tendon. In *Injury and Repair of the Musculoskeletal Soft Tissues: Workshop, Savannah, Georgia, June 1987*, pp. 1-40. Edited by S. L.-Y. Woo and J. A. Buckwalter. Park Ridge, Illinois, American Academy of Orthopaedic Surgeons, 1988.
  19. **Ghadially, F. N.:** Extracellular matrix (extracellular components). In *Ultrastructural Pathology of the Cell and Matrix. A Text and Atlas of Physiological and Pathological Alterations in the Fine Structure of Cellular and Extracellular Components*. Ed. 3, vol. 2, pp. 1215-1303. Boston, Butterworth, 1988.
  20. **Goldie, I.:** Epicondylitis lateralis humeri (epicondylalgia or tennis elbow). A pathological study. *Acta Chir. Scandinavica*, Supplementum 339, 1964.
  21. **Hildebrand, K. A.; Woo, S. L.; Smith, D. W.; Allen, C. R.; Deie, M.; Taylor, B. J.; and Schmidt, C. C.:** The effects of platelet-derived growth factor-BB on healing of the rabbit medial collateral ligament. *Am. J. Sports Med.*, 26: 549-554, 1998.
  22. **Iwasaki, M.; Nakahara, H.; Nakata, K.; Nakase, T.; Kimura, T.; and Ono, K.:** Regulation of proliferation and osteochondrogenic differentiation of periosteum-derived cells by transforming growth factor- $\beta$  and basic fibroblast growth factor. *J. Bone and Joint Surg.*, 77-A: 543-554, April 1995.
  23. **Józsa, L.; Kvist, M.; Balint, B. J.; Reffy, A.; Jarvinen, M.; Lehto, M.; and Barzo, M.:** The role of recreational sport activity in Achilles tendon rupture. A clinical, pathoanatomical, and sociological study of 292 cases. *Am. J. Sports Med.*, 17: 338-343, 1989.
  24. **Józsa, L.; Lehto, M.; Kvist, M.; Balint, J. B.; and Reffy, A.:** Alterations in dry mass content of collagen fibers in degenerative tendinopathy and tendon-rupture. *Matrix*, 9: 140-146, 1989.
  25. **Józsa, L.; Reffy, A.; Kannus, P.; Demel, S.; and Elek, E.:** Pathological alterations in human tendons. *Arch. Orthop. and Trauma Surg.*, 110: 15-21, 1990.
  26. **Józsa, L. G., and Kannus, P.** [editors]: Overuse injuries of tendons. In *Human Tendons: Anatomy, Physiology, and Pathology*, pp. 164-253. Champaign, Illinois, Human Kinetics, 1997.
  27. **Kannus, P., and Józsa, L.:** Histopathological changes preceding spontaneous rupture of a tendon. A controlled study of 891 patients. *J. Bone and Joint Surg.*, 73-A: 1507-1525, Dec. 1991.
  28. **Kapetanos, G.:** The effect of the local corticosteroids on the healing and biomechanical properties of the partially injured tendon. *Clin. Orthop.*, 163: 170-179, 1982.
  29. **Kibler, W. B.:** Concepts in exercise rehabilitation of athletic injury. In *Sports-Induced Inflammation: Clinical and Basic Science Concepts*, pp. 759-769. Edited by W. B. Leadbetter, J. A. Buckwalter, and S. L. Gordon. Park Ridge, Illinois, American Academy of Orthopaedic Surgeons, 1990.
  30. **Kibler, W. B.; Chandler, T. J.; and Pace, B. K.:** Principles of rehabilitation after chronic tendon injuries. *Clin. Sports Med.*, 11: 661-671, 1992.
  31. **Kibler, W. B.:** Clinical implications of exercise: injury and performance. In *Instructional Course Lectures, American Academy of Orthopaedic Surgeons*. Vol. 43, pp. 17-24. Rosemont, Illinois, American Academy of Orthopaedic Surgeons, 1994.
  32. **Klein, L., and Lewis, J. A.:** Simultaneous quantification of  $^3\text{H}$ -collagen loss and  $^1\text{H}$ -collagen replacement during healing of rat tendon grafts. *J. Bone and Joint Surg.*, 54-A: 137-146, Jan. 1972.
  33. **Kraushaar, B. S., and Nirschl, R. P.:** Pearls: handshake lends epicondylitis cues. *Phys. Sportsmed.*, 24(9): 15, 1996.
  34. **Leadbetter, W. B.:** Corticosteroid injection therapy in sports injuries. In *Sports-Induced Inflammation: Clinical and Basic Science Concepts*, pp. 527-545. Edited by W. B. Leadbetter, J. A. Buckwalter, and S. L. Gordon. Park Ridge, Illinois, American Academy of Orthopaedic Surgeons, 1990.
  35. **Leadbetter, W. B.:** Cell-matrix response in tendon injury. *Clin. Sports Med.*, 11: 533-578, 1992.
  36. **Lundborg, G., and Rank, F.:** Experimental studies on cellular mechanisms involved in healing of animal and human flexor tendon in synovial environment. *Hand*, 12: 3-11, 1980.
  37. **Majamaa, K.:** Effect of prevention of procollagen triple-helix formation on proline 3-hydroxylation in freshly isolated chick-embryo tendon cells. *Biochem. J.*, 196: 203-206, 1981.
  38. **Mason, M. L., and Allen, H. S.:** The rate of healing of tendons. An experimental study of tensile strength. *Ann. Surg.*, 113: 424-459, 1941.
  39. **Mechanic, G. L.:** The intermolecular cross-link precursors in collagens as related to function. Identification of  $\gamma$ -hydroxy and  $\alpha$ -amino adipic semialdehyde in tendon collagen. *Israel J. Med. Sci.*, 7: 453-462, 1971.
  40. **Menard, D., and Stanish, W. D.:** The aging athlete. *Am. J. Sports Med.*, 17: 187-196, 1989.
  41. **Nirschl, R. P.:** Mesenchymal syndrome. *Virginia Med. Monthly*, 96: 659-662, 1969.
  42. **Nirschl, R. P., and Petrone, F. A.:** Tennis elbow. The surgical treatment of lateral epicondylitis. *J. Bone and Joint Surg.*, 61-A: 832-839, Sept. 1979.
  43. **Nirschl, R. P.:** Prevention and treatment of elbow and shoulder injuries in the tennis player. *Clin. Sports Med.*, 7: 289-308, 1988.
  44. **Nirschl, R. P.:** Rotator cuff tendinitis: basic concepts of pathoetiology. In *Instructional Course Lectures, American Academy of Orthopaedic Surgeons*. Vol. 38, pp. 439-445. Edited by J. S. Barr, Jr. Park Ridge, Illinois, American Academy of Orthopaedic Surgeons, 1989.
  45. **Nirschl, R. P.:** Patterns of failed tendon healing in tendon injury. In *Sports-Induced Inflammation: Clinical and Basic Science Concepts*, pp. 609-618. Edited by W. B. Leadbetter, J. A. Buckwalter, and S. L. Gordon. Park Ridge, Illinois, American Academy of Orthopaedic Surgeons, 1990.
  46. **Nirschl, R. P.:** Elbow tendinosis/tennis elbow. *Clin. Sports Med.*, 11: 851-870, 1992.
  47. **Nirschl, R. P.:** Lateral and medial epicondylitis. In *Masters Techniques in Orthopaedic Surgery. The Elbow*, edited by B. F. Morrey. New York, Raven Press, 1994.
  48. **Nirschl, R. P.:** Tennis elbow tendinosis: pathoanatomy, nonsurgical and surgical management. In *Repetitive Motion Disorders of the Upper Extremity*, pp. 467-479. Edited by S. L. Gordon, S. J. Blair, and L. J. Fine. Rosemont, Illinois, American Academy of Orthopaedic Surgeons, 1995.

49. **Nirschl, R. P., and Sobel, J.:** *Arm Care. A Complete Guide to Prevention and Treatment of Tennis Elbow.* Arlington, Virginia, Medical Sports, 1996.
50. **Novacheck, T. F.:** Running injuries: a biomechanical approach. *J. Bone and Joint Surg.*, 80-A: 1220-1233, Aug. 1998.
51. **O'Brien, M.:** Functional anatomy and physiology of tendons. *Clin. Sports Med.*, 11: 505-520, 1992.
52. **Ollivierre, C. O.; Nirschl, R. P.; and Pettrone, F. A.:** Resection and repair for medial tennis elbow. A prospective analysis. *Am. J. Sports Med.*, 23: 214-221, 1995.
53. **Organ, S. W.; Nirschl, R. P.; Kraushaar, B. S.; and Guidi, E. J.:** Salvage surgery for lateral tennis elbow. *Am. J. Sports Med.*, 25: 746-750, 1997.
54. **Peacock, E. E., Jr.:** Fundamental aspects of wound healing relating to the restoration of gliding function after tendon repair. *Surg., Gynec. and Obstet.*, 119: 241-250, 1964.
55. **Perugia, L.; Ricciardi Pollini, P. T.; and Ippolito, E.:** Ultrastructural aspects of degenerative tendinopathy. *Internat. Orthop.*, 1: 303-307, 1978.
56. **Potenza, A. D.:** Tendon and ligament healing. In *Scientific Foundations of Orthopaedics and Traumatology*, pp. 300-305. Edited by R. Owen, J. Goodfellow, and P. Bullough. Philadelphia, W. B. Saunders, 1980.
57. **Puddu, G.; Ippolito, E.; and Postacchini, F.:** A classification of Achilles tendon disease. *Am. J. Sports Med.*, 4: 145-150, 1976.
58. **Rathbun, J. B., and Macnab, I.:** The microvascular pattern of the rotator cuff. *J. Bone and Joint Surg.*, 52-B(3): 540-553, 1970.
59. **Regan, W.; Wold, L. E.; Coonrad, R.; and Morrey, B. F.:** Microscopic histopathology of chronic refractory lateral epicondylitis. *Am. J. Sports Med.*, 20: 746-749, 1992.
60. **Ross, R.:** The fibroblast and wound repair. *Biol. Rev.*, 43: 51-96, 1968.
61. **Saltzman, C. L., and Tearse, D. S.:** Achilles tendon injuries. *J. Am. Acad. Orthop. Surgeons*, 6: 316-325, 1998.
62. **Sarkar, K., and Uthoff, H. K.:** Ultrastructural localization of calcium in calcifying tendinitis. *Arch. Pathol. Lab. Med.*, 102: 266-269, 1978.
63. **Sarkar, K., and Uthoff, H. K.:** Ultrastructure of the common extensor tendon in tennis elbow. *Virchows Arch. A, Pathol. Anat. and Histol.*, 386: 317-330, 1980.
64. **Stahl, S., and Kaufman, T.:** The efficacy of an injection of steroids for medial epicondylitis. A prospective study of sixty elbows. *J. Bone and Joint Surg.*, 79-A: 1648-1652, Nov. 1997.
65. **Stanish, W. D.; Rubinovich, R. M.; and Curwin, S.:** Eccentric exercise in chronic tendinitis. *Clin. Orthop.*, 208: 65-68, 1986.
66. **Teitz, C. C.; Garrett, W. E., Jr.; Miniaci, A.; Lee, M. H.; and Mann, R. A.:** Tendon problems in athletic individuals. *J. Bone and Joint Surg.*, 79-A: 138-152, Jan. 1997.
67. **Uthoff, H. K.; Sarkar, K.; and Maynard, J. A.:** Calcifying tendinitis. A new concept of its pathogenesis. *Clin. Orthop.*, 118: 164-168, 1976.
68. **Weiss, J. A.:** The cell. In *Cell Tissue and Biology. A Textbook of Histology*, edited by L. Weiss. Ed. 6, p. 22. Baltimore, Urban and Schwarzenberg, 1988.
69. **Wheater, P. R.; Burkitt, H. G.; and Daniels, V. G.:** Supporting/connective tissues. In *Wheater's Functional Histology: A Text and Colour Atlas*, edited by H. G. Burkitt, B. Young, and J. W. Heath. Ed. 3, pp. 61-74. New York, Churchill Livingstone, 1993.
70. **Woo, S. L-Y.; Gomez, M. A.; Woo, Y. K.; and Akeson, W. H.:** Mechanical properties of tendons and ligaments. II. The relationships of immobilization and exercise on tissue remodeling. *Biorheology*, 19: 397-408, 1982.
71. **Woo, S. L-Y., and Tkach, L. V.:** The cellular and matrix response of ligaments and tendons to mechanical injury. In *Sports-Induced Inflammation: Clinical and Basic Science Concepts*, pp. 189-202. Edited by W. B. Leadbetter, J. A. Buckwalter, and S. L. Gordon. Park Ridge, Illinois, American Academy of Orthopaedic Surgeons, 1990.
72. **Woo, S. L-Y.; An, K.-N.; Arnoczky, S. P.; Wayne, J. S.; Fithian, D. C.; and Myers, B. S.:** Anatomy, biology, and biomechanics of tendon, ligament, and meniscus. In *Orthopaedic Basic Science*, pp. 45-87. Edited by S. R. Simon. Rosemont, Illinois, American Academy of Orthopaedic Surgeons, 1994.
73. **Yamamoto, N.; Ohno, K.; Hayashi, K.; Kuriyama, H.; Yasuda, K.; and Kaneda, K.:** Effects of stress shielding on the mechanical properties of rabbit patellar tendon. *J. Biomech. Eng.*, 115: 23-28, 1993.